

INFI-CG 2016

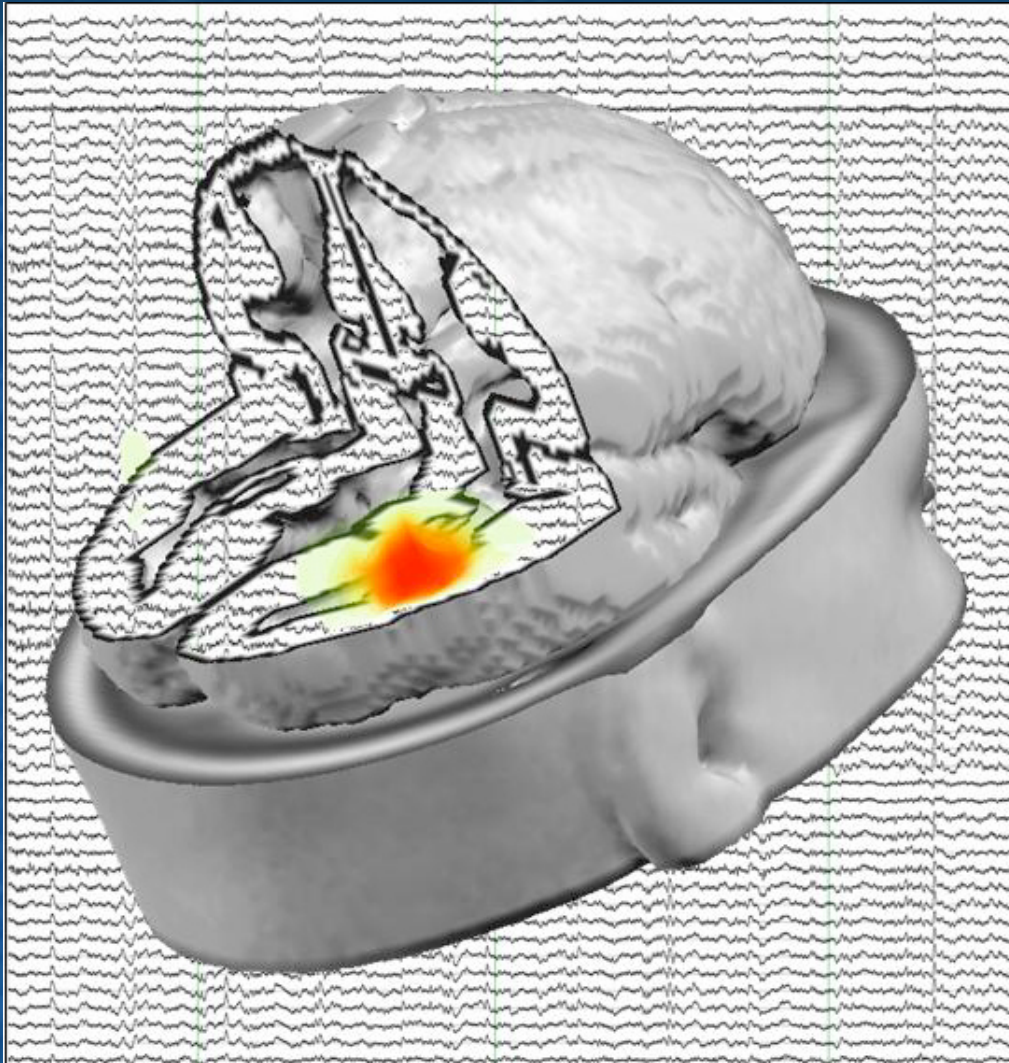
Lecture 28

Introduction to Cognitive
Neuroscience: How can we look
at what's going on in the brain

Richard Shillcock

Goals

Understand the principles of brain imaging and the kinds of data that can be revealed



Readings

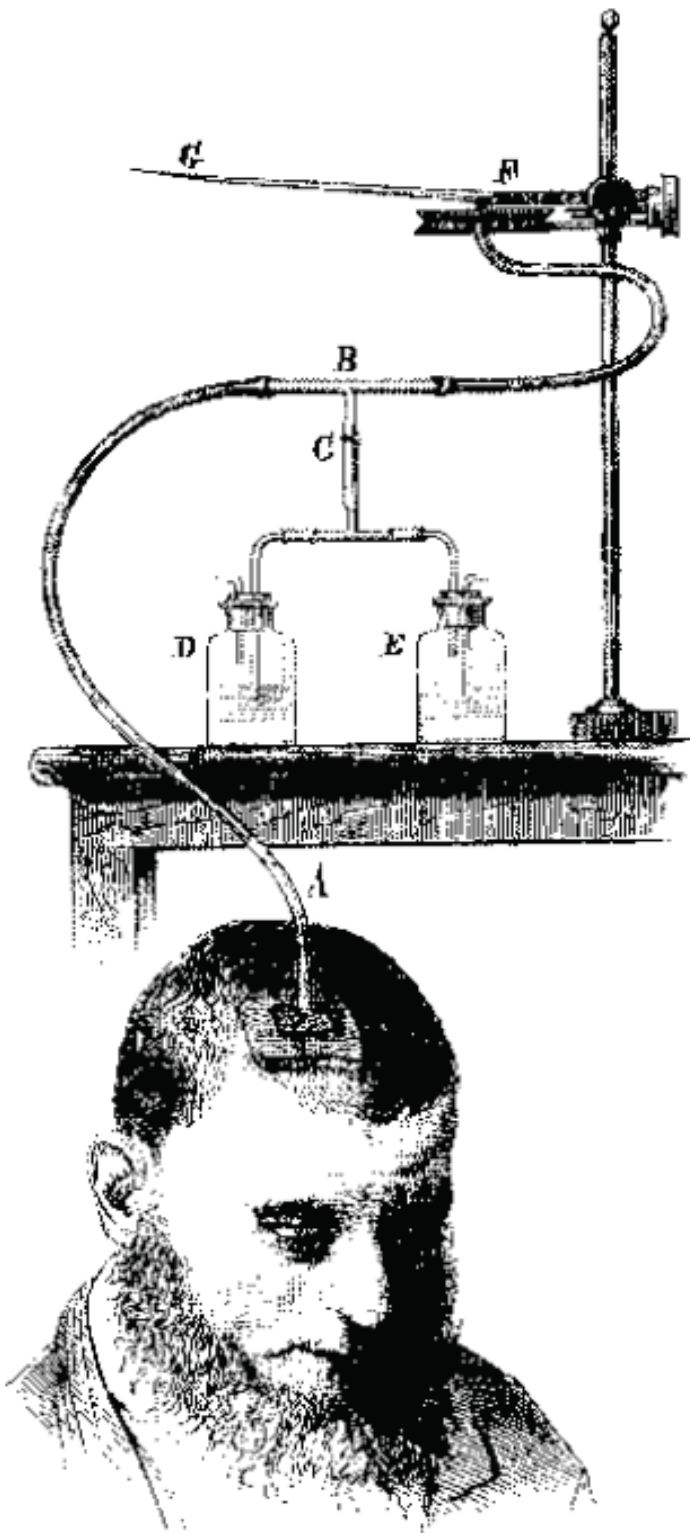
Page, M. (2006). What can't functional neuroimaging tell the cognitive psychologist? *Cortex*, 42, 428-443.



Coltheart, M. (2006). Perhaps functional neuroimaging has not told us anything about the mind (so far). *Cortex*, 42, 422-427.


History

Mosso & Pellacini (1881) conclude that behaviour changes cause changes in blood flow to the brain, measuring a pulse in an abnormality in Bertino's skull.



History

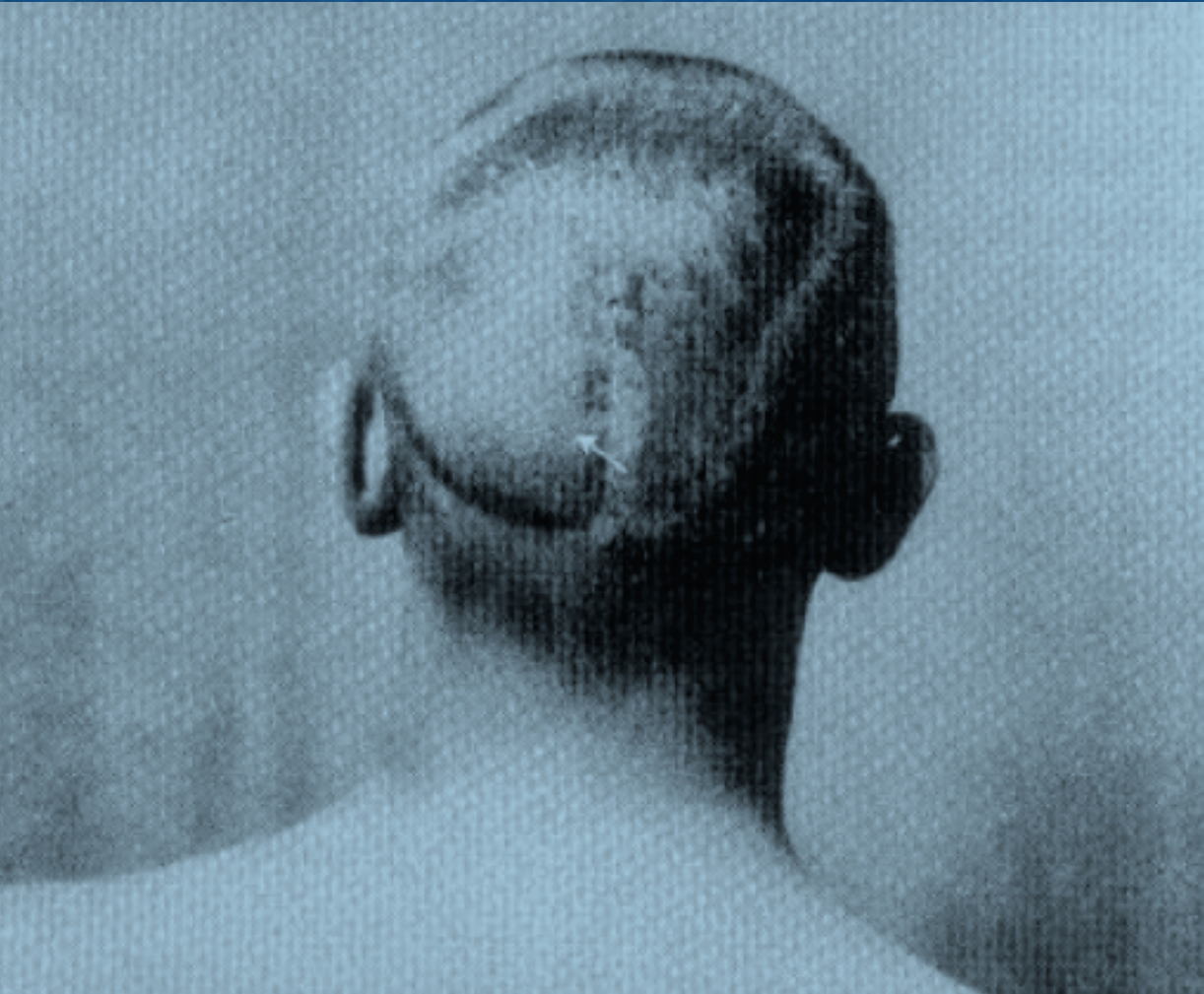Mosso & Pellacini (1881) conclude that behaviour changes cause changes in blood flow to the brain, measuring a pulse in an abnormality in Bertino's skull.



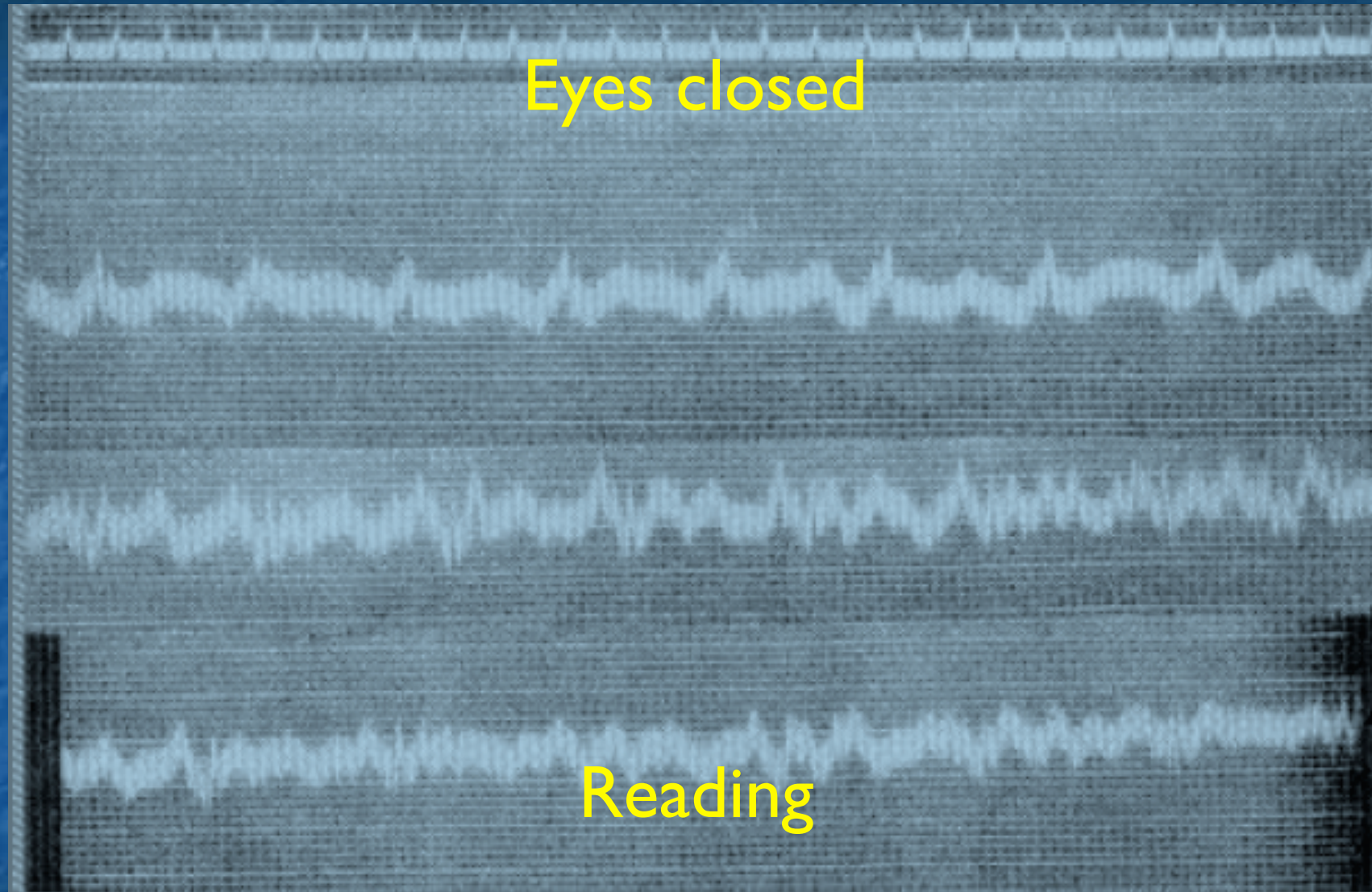
(A = forearm, C = brain)

History

Fulton (1928) listens to the arteriovenous malformation in patient Walter K's skull.



History



Fulton (1928) listens to the arteriovenous malformation in patient Walter K's skull.

Imaging techniques

Near Infra-Red Spectroscopy (NIRS)

Doppler sonography

Positron Emission Tomography (PET)

Magneto-Encephalography (MEG)

Functional Magnetic Resonance (fMRI)

Electro Encephalography (EEG)

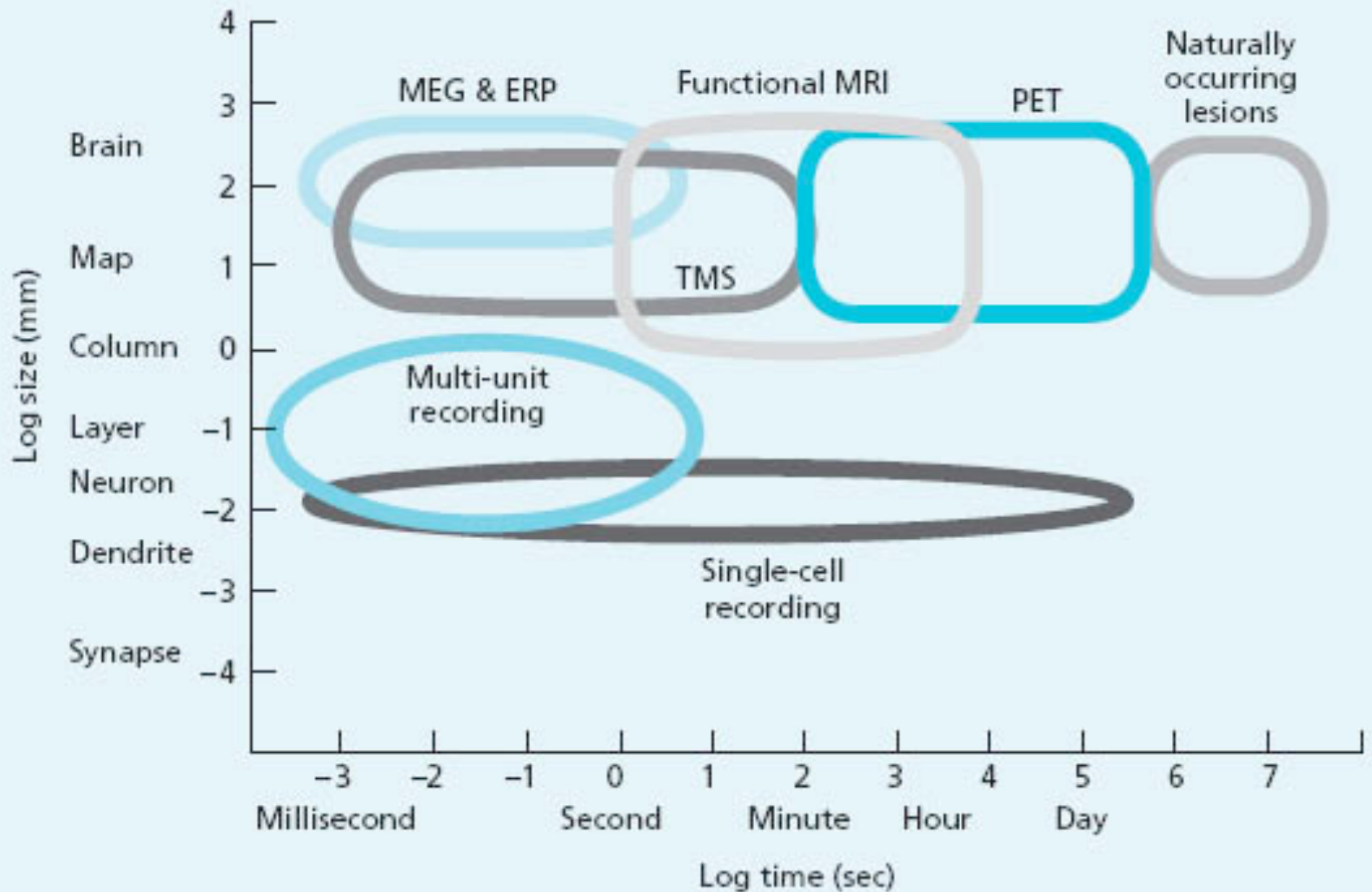
Diffusion tensor tractography

Transcranial Magnetic Stimulation (TMS)

Direct Current Stimulation (DCS)

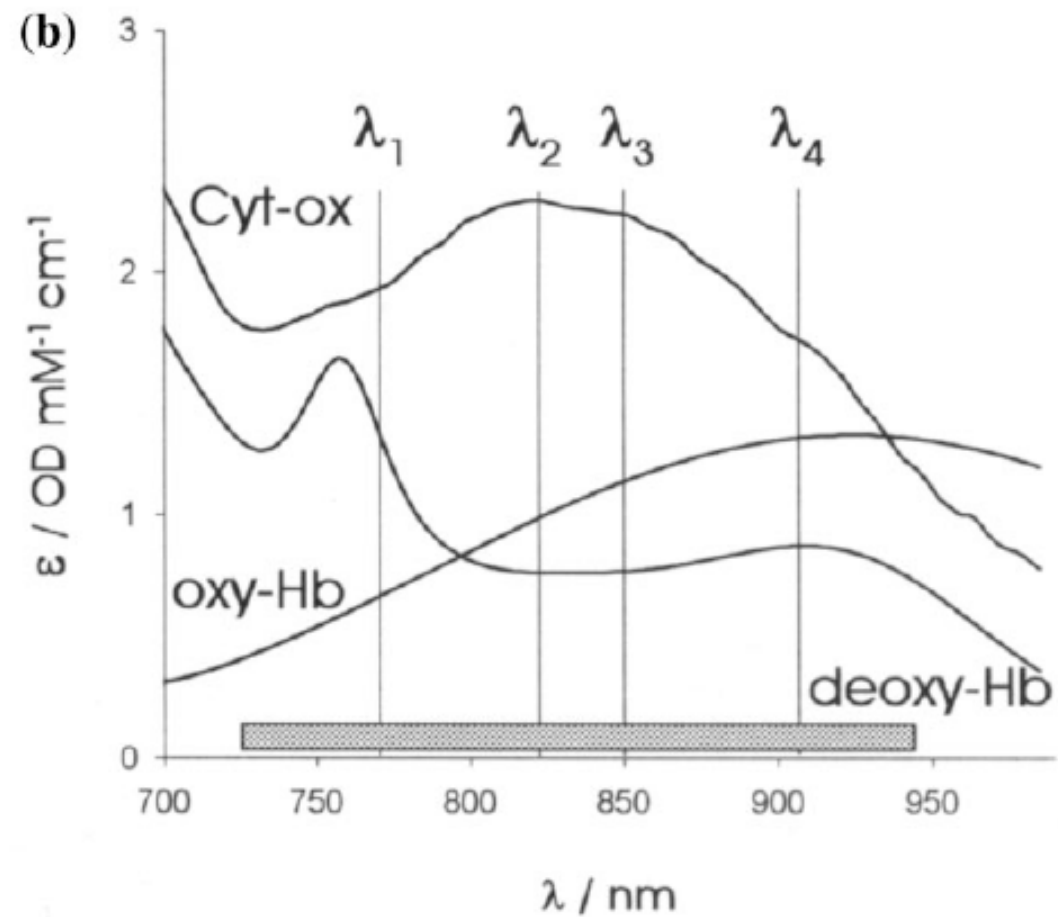
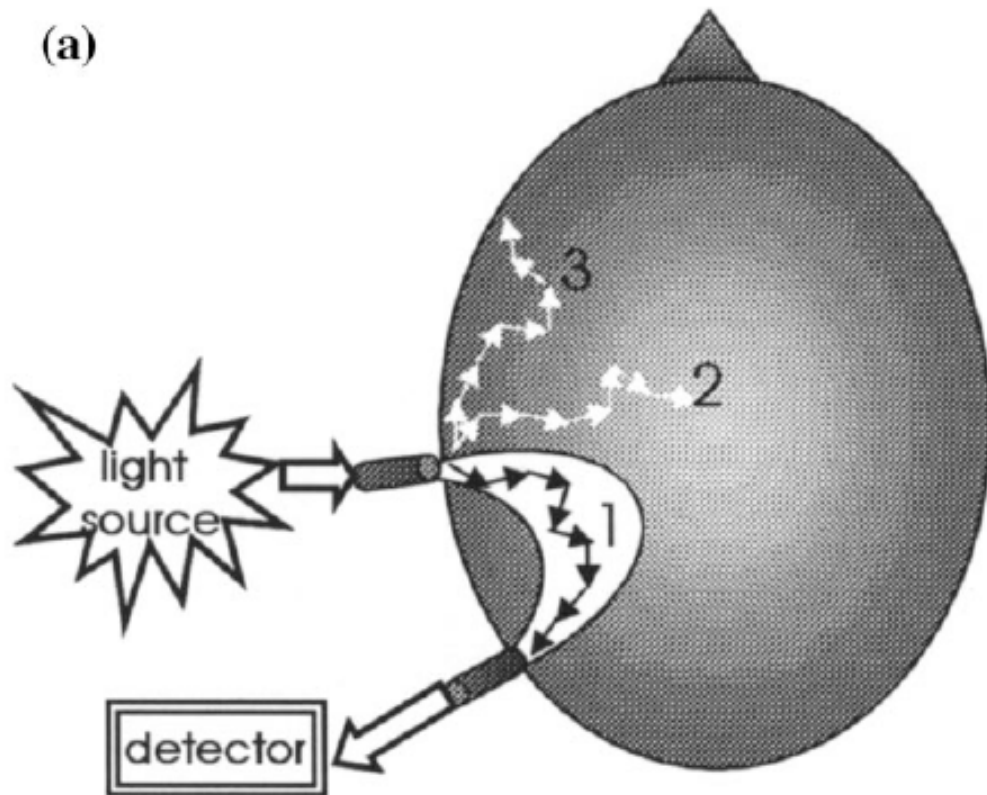
Single cell recording

Specificity of imaging techniques



Near Infra-Red Spectroscopy

Obrig *et al.* (2000)

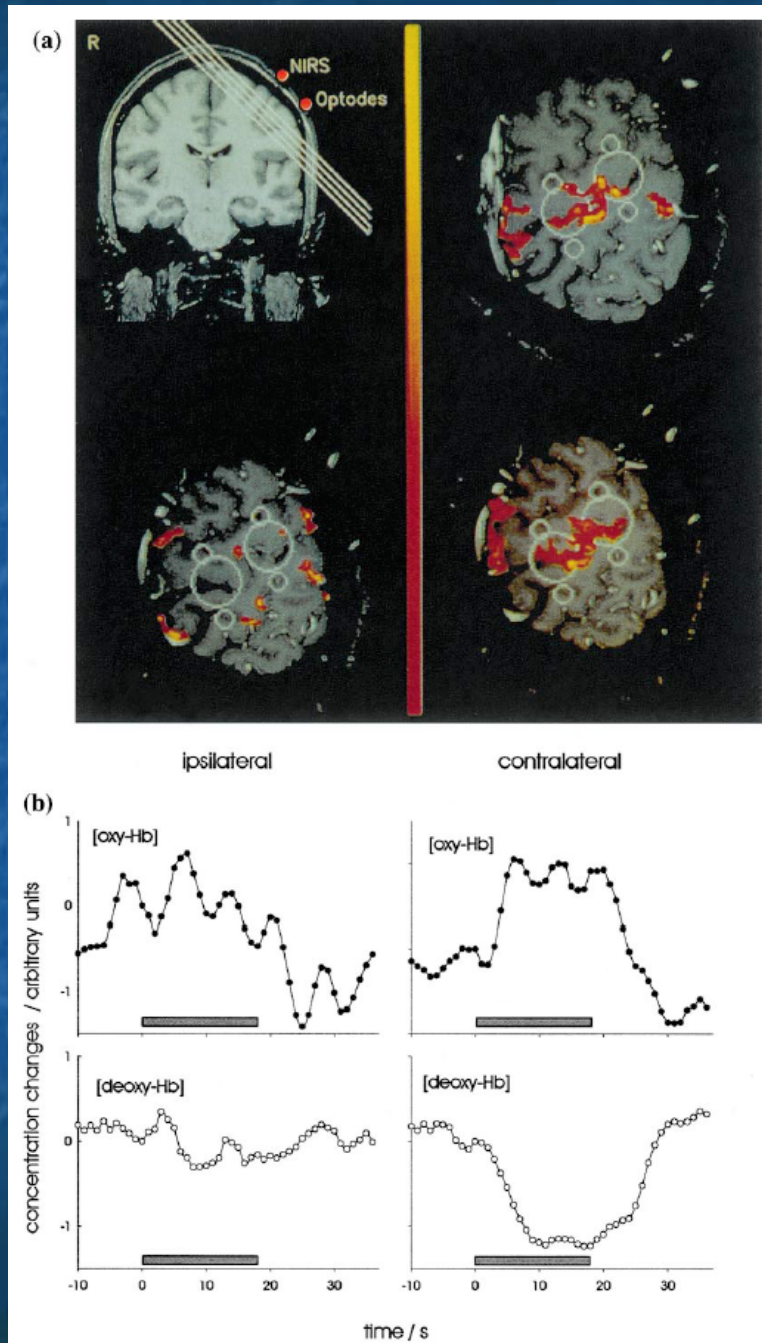


Near Infra-Red Spectroscopy

Obrig *et al.* (2000)

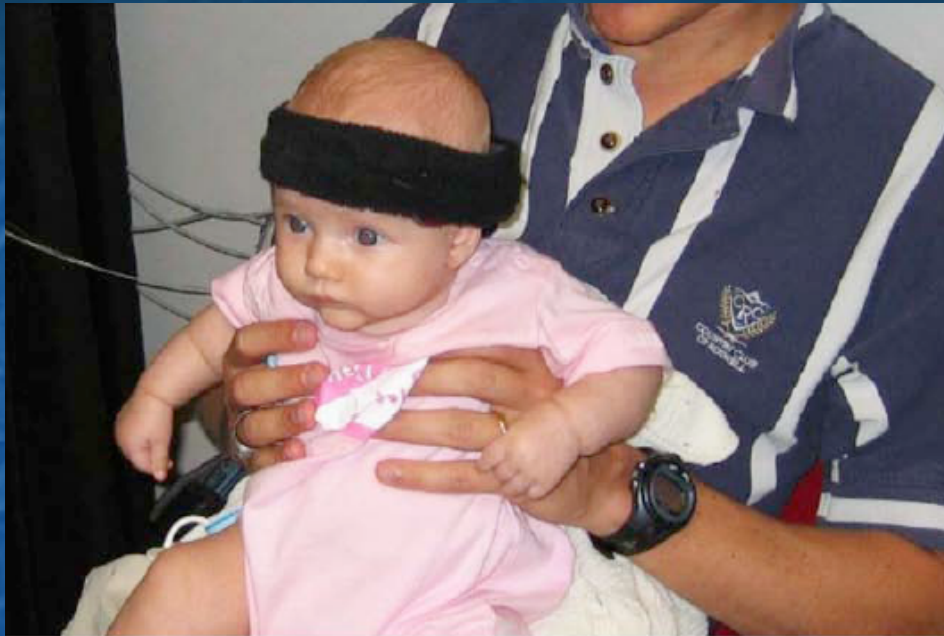fMRI

NIRS

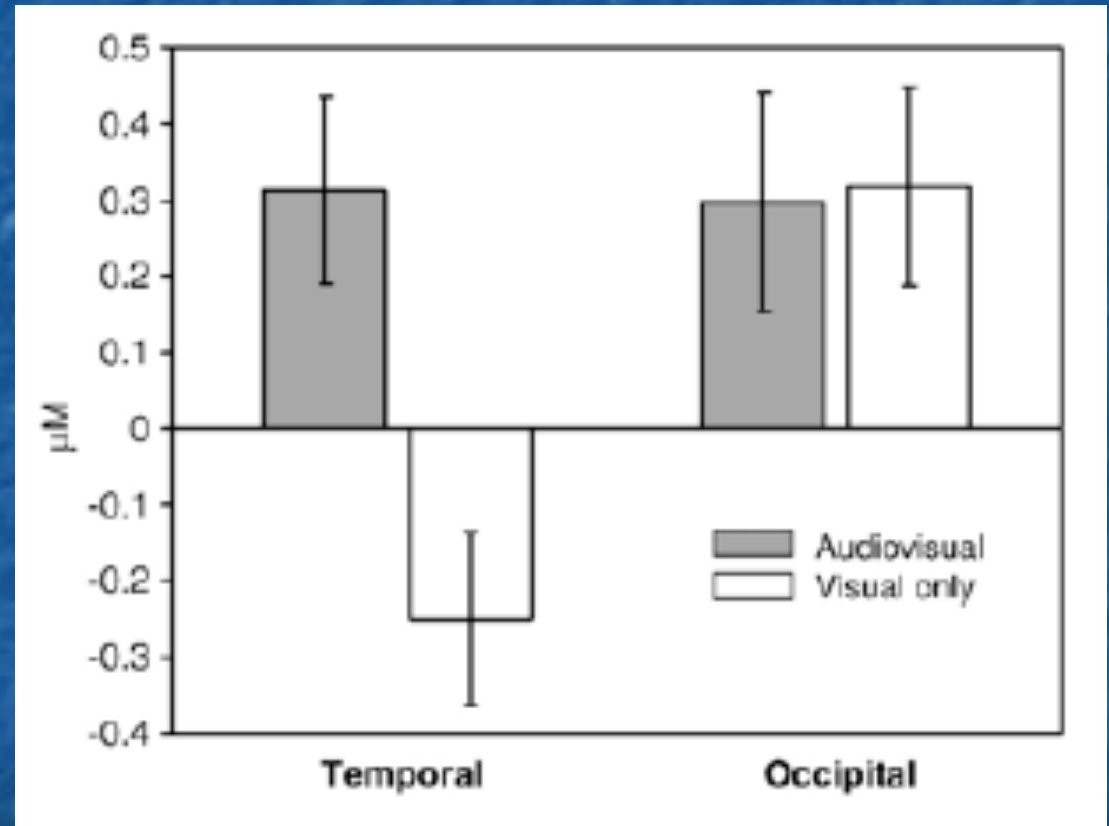


Near Infra-Red Spectroscopy

Bortfeld *et al.* (2007)



(b)



(Graph shows concentration of deoxygenated blood.)

Doppler sonography

Knecht *et al.* (1998)

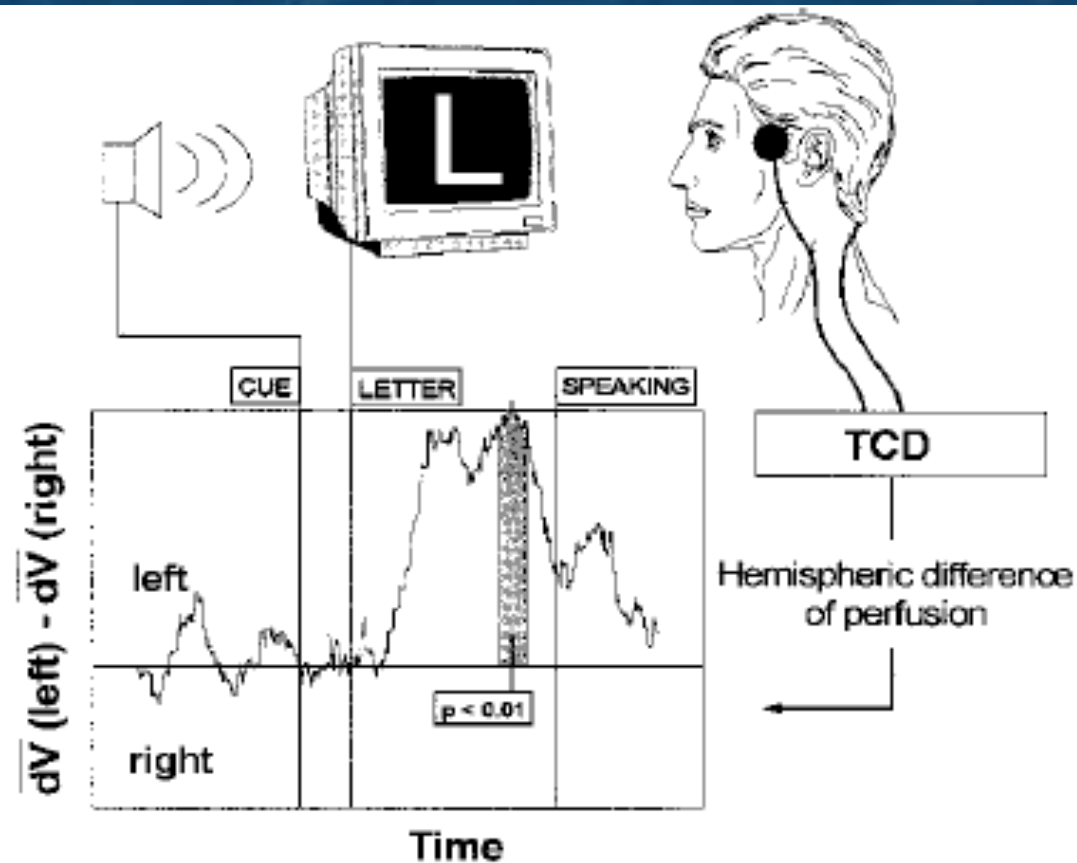
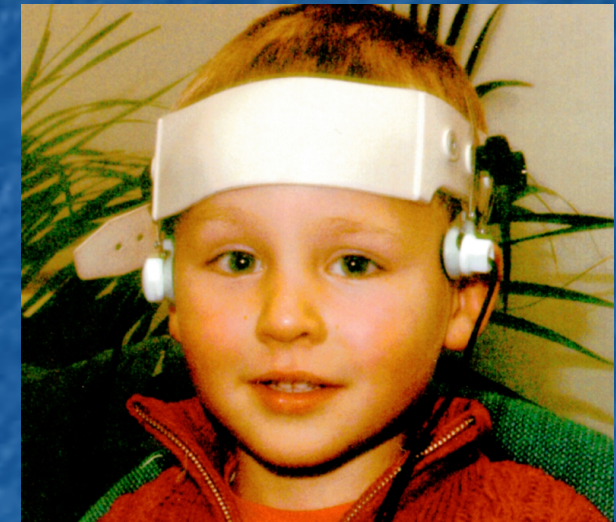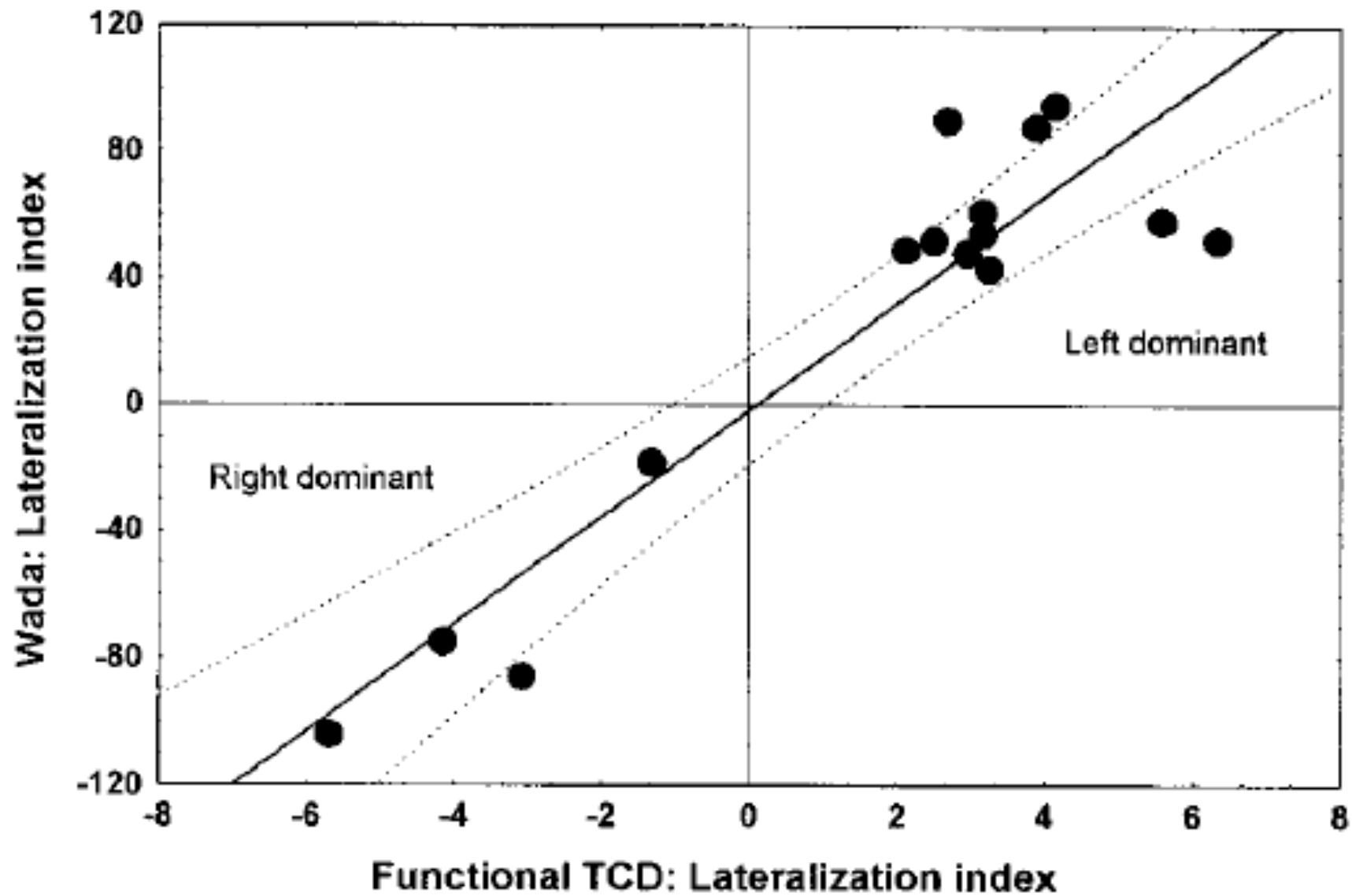


Figure 1. Experimental setup of language dominance assessment by fTCD. Displayed data represent the averaged results from 20 letter presentations in a single subject. Note the delay of approximately 4 to 7 seconds before the maximal hemispheric difference is reached. dV indicates relative CBFV changes.



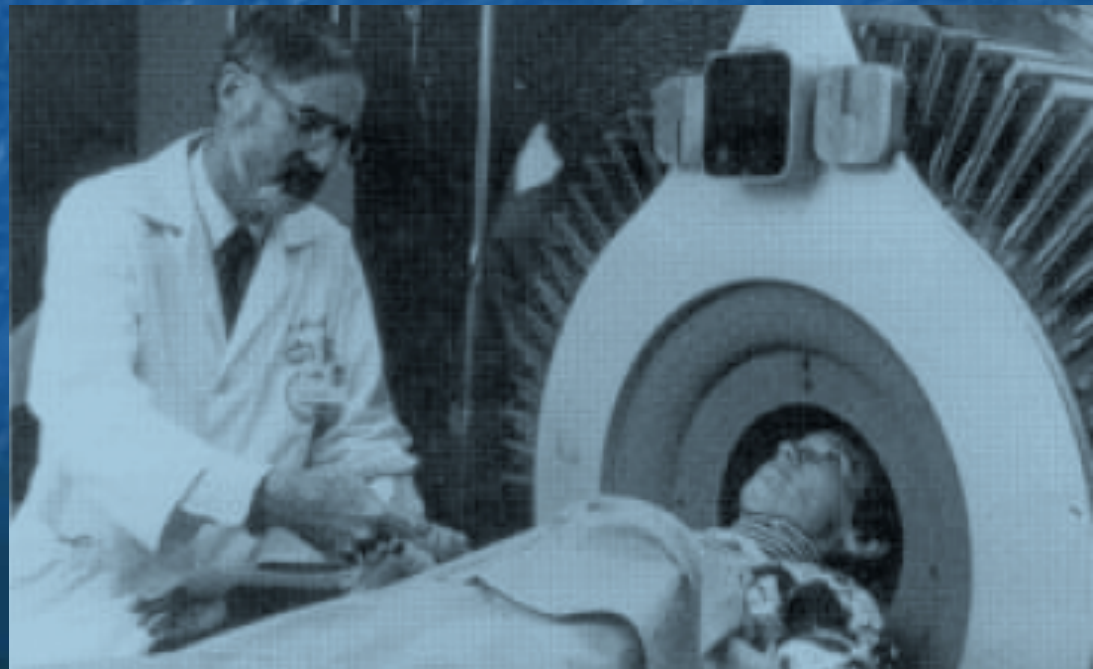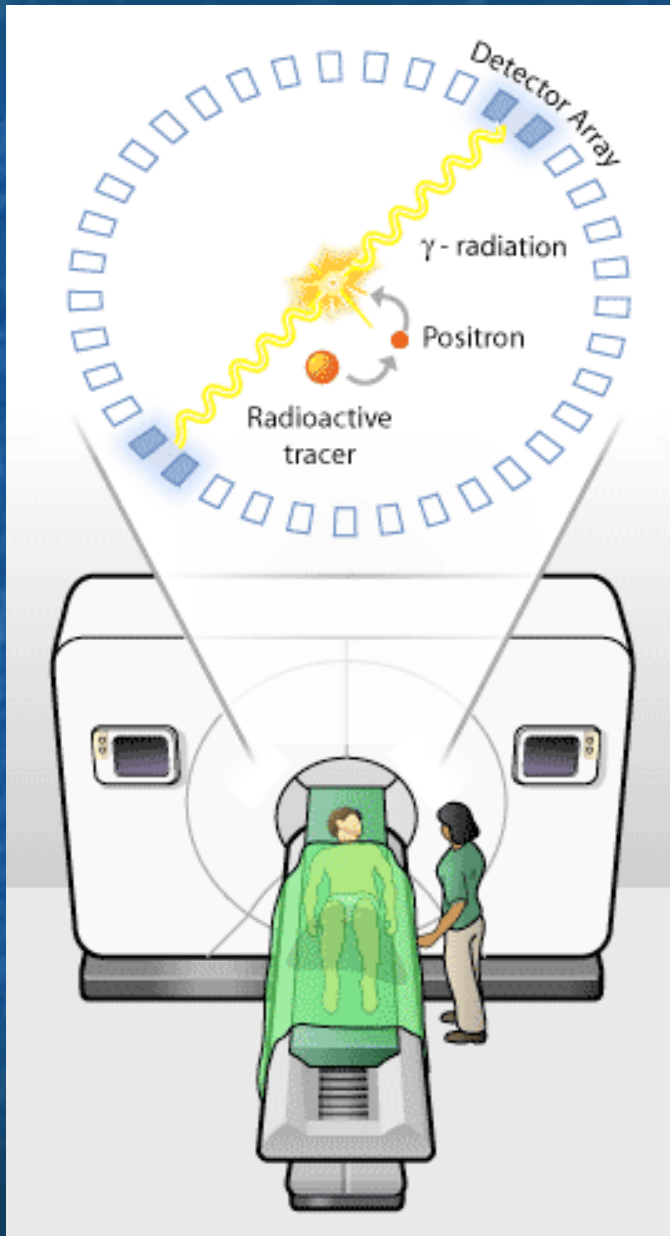
Doppler sonography

Knecht *et al.* (1998)

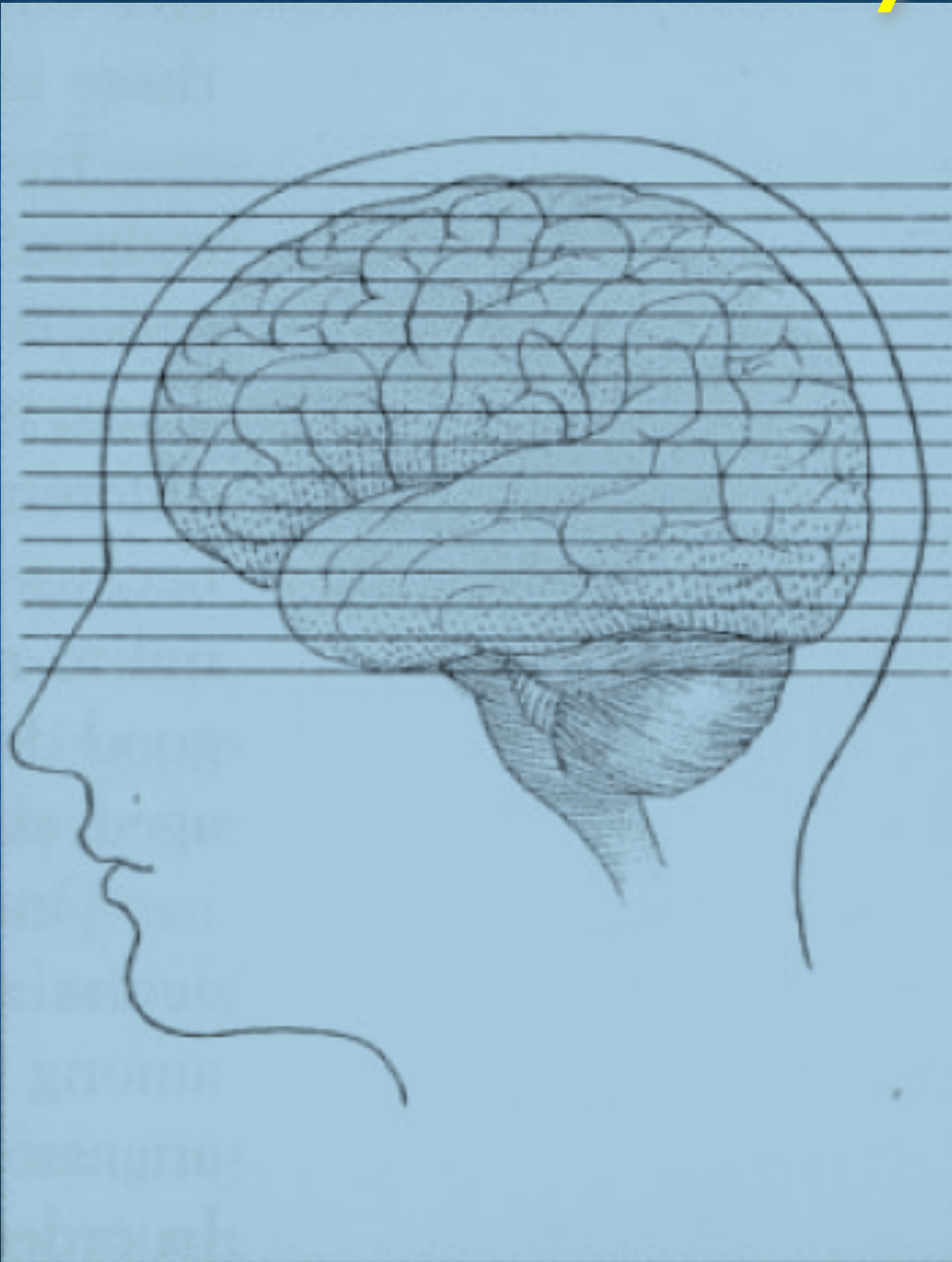


Haemodynamic methods: PET

Radioactive water is injected into the participant and radioactive decay releases pairs of high-energy photons that leave the skull and are monitored.



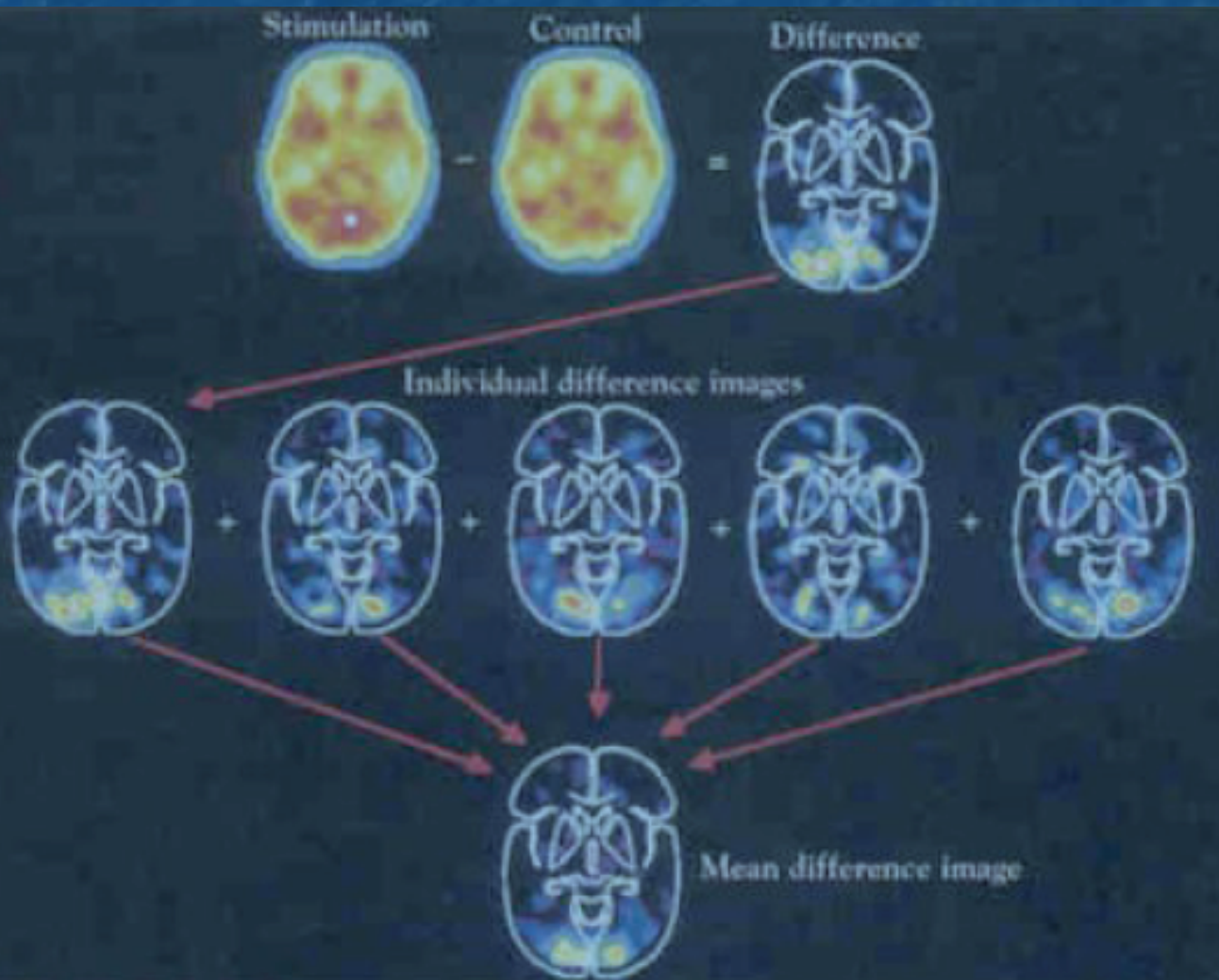
Haemodynamic methods: PET



Parallel slices are imaged.

Such methods necessarily produce a *partial* view.

Haemodynamic methods: PET




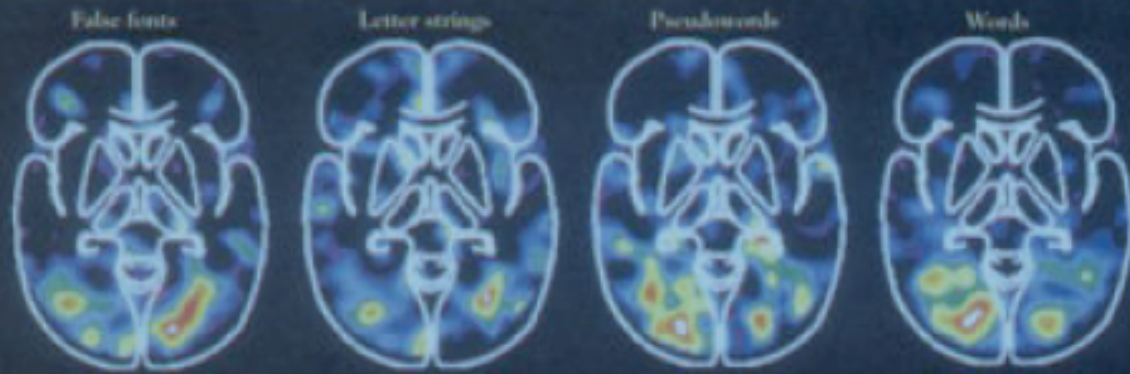
The control condition is subtracted from the experimental condition (e.g. low-level vision task *versus* reading).

Data are averaged over several participants.

PET: localization of function

Posner & Raichle (1994)

More LH activity for more word-like stimuli.



Example of the Four Types of Visual Stimuli

False Fonts	Letterstrings	Pseudowords	Words
RR3	USFFHT	GEEL	ANT
J9J9	TBBL	IOB	RAZOR
Y0Y9	TSTFS	RELD	DUST
1-00	JBTT	BLERCE	FURNACE
887J9	STB	CHELDINABE	MOTHER
K108	FFPW	ALDOBER	FARM

Haemodynamic methods: PET

The K family

Vargha-Khadem *et al.* (1995)

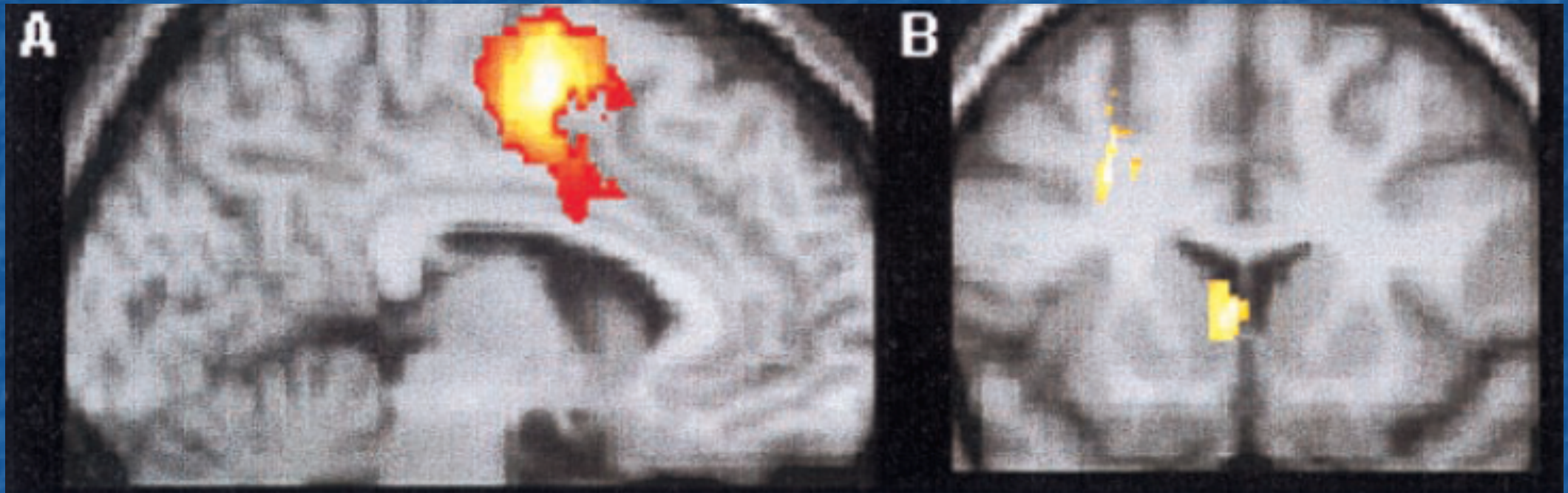


FIG. 3. Results of SPM analysis of PET data (*A* and *B*; see also Table 1) and MRI data (*C*; see also Table 2). (*A*) Parasagittal section through left hemisphere, 6 mm from midline. Colored area, encompassing parts of SMA, preSMA, and cingulate cortices, indicates a region that was less active in the affected family members than in the controls. (*B*) Coronal section, 14 mm in front of the coronal plane through the anterior commissure. Colored areas, located in the head of the left caudate nucleus and left premotor cortex, indicate regions that were more active in the affected family members than in the controls. (*C*) Transverse section, 2 mm above the transverse plane through the anterior and posterior commissures. Colored

Haemodynamic methods: MRI

Vargha-Khadem *et al.* (1995)

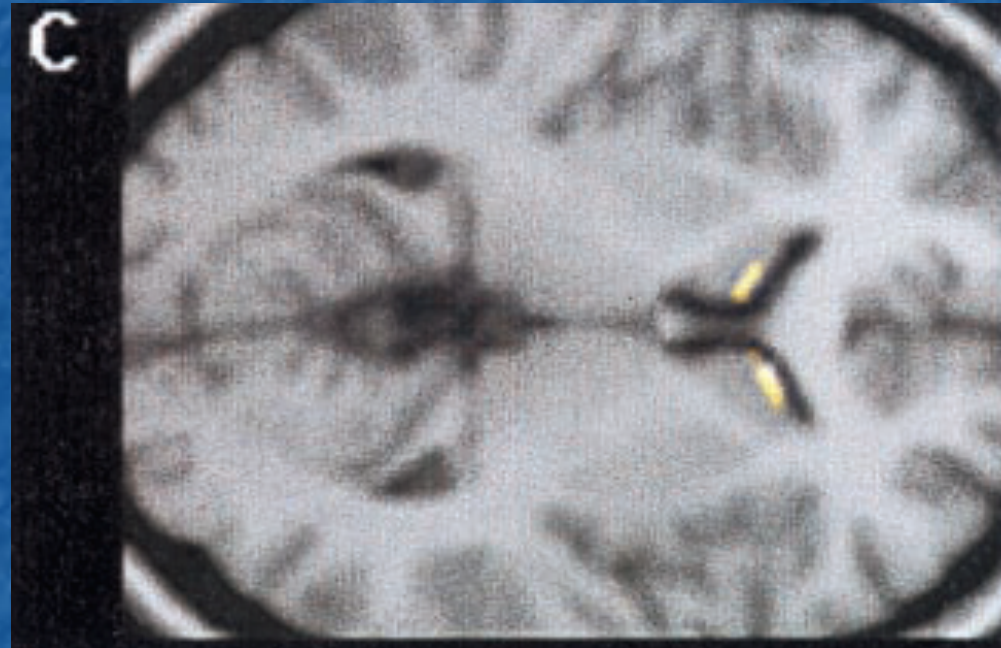


FIG. 3. Results of SPM analysis of PET data (*A* and *B*; see also Table 1) and MRI data (*C*; see also Table 2). (*A*) Parasagittal section through left hemisphere, 6 mm from midline. Colored area, encompassing parts of SMA, preSMA, and cingulate cortices, indicates a region that was less active in the affected family members than in the controls. (*B*) Coronal section, 14 mm in front of the coronal plane through the anterior commissure. Colored areas, located in the head of the left caudate nucleus and left premotor cortex, indicate regions that were more active in the affected family members than in the controls. (*C*) Transverse section, 2 mm above the transverse plane through the anterior and posterior commissures. Colored areas, located in the head of the caudate nucleus bilaterally, indicate areas that had less gray matter in the group of affected than in the group of unaffected family members ($n = 6$ and 7 , respectively).

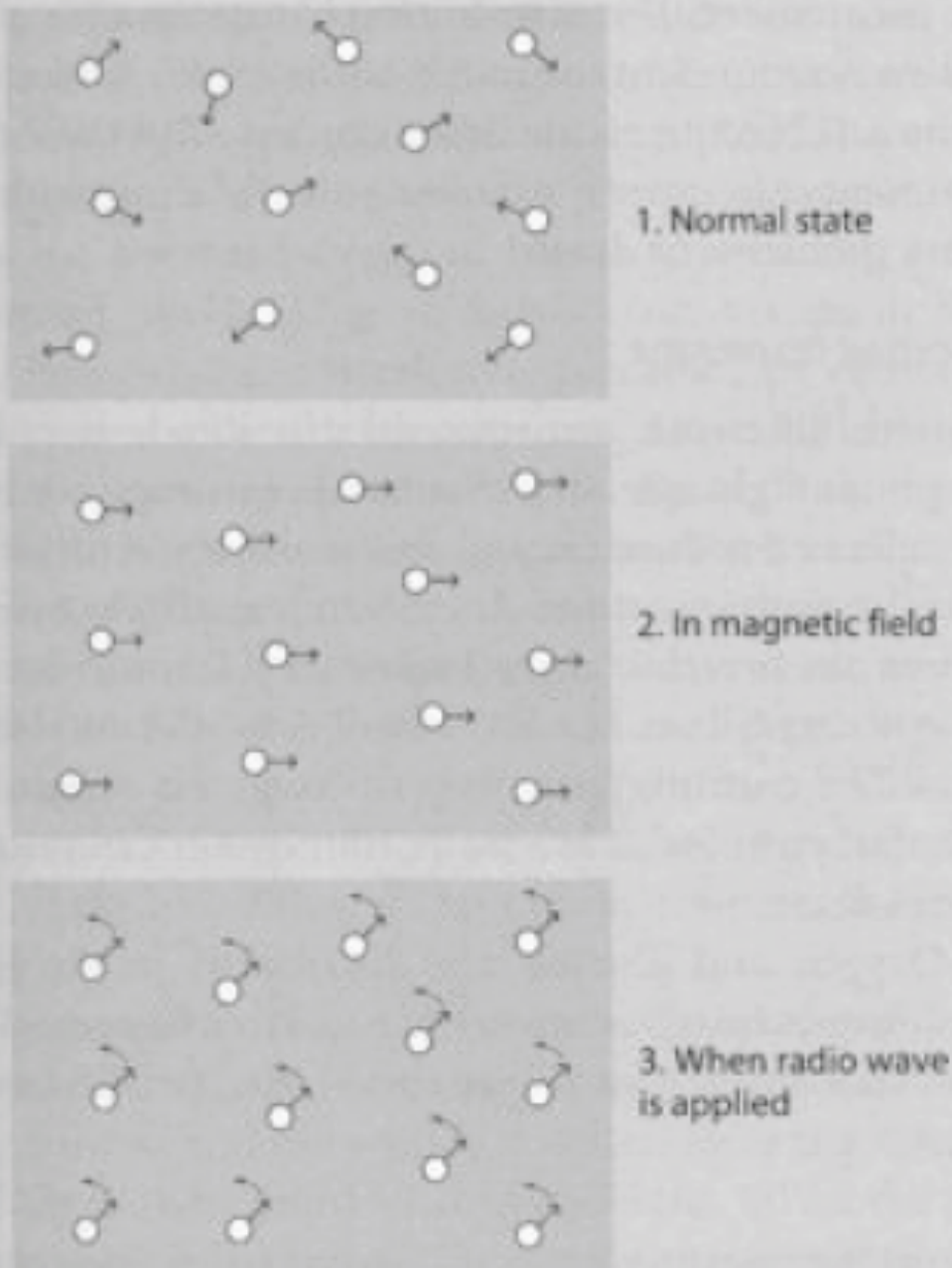
Haemodynamic methods: MRI



In magnetic resonance imaging, a powerful magnetic field aligns the protons (mostly relying on the hydrogen in the body).

An electromagnetic pulse then perturbs the alignment and causes photons to be emitted.

Haemodynamic methods: MRI



These are monitored by the device.

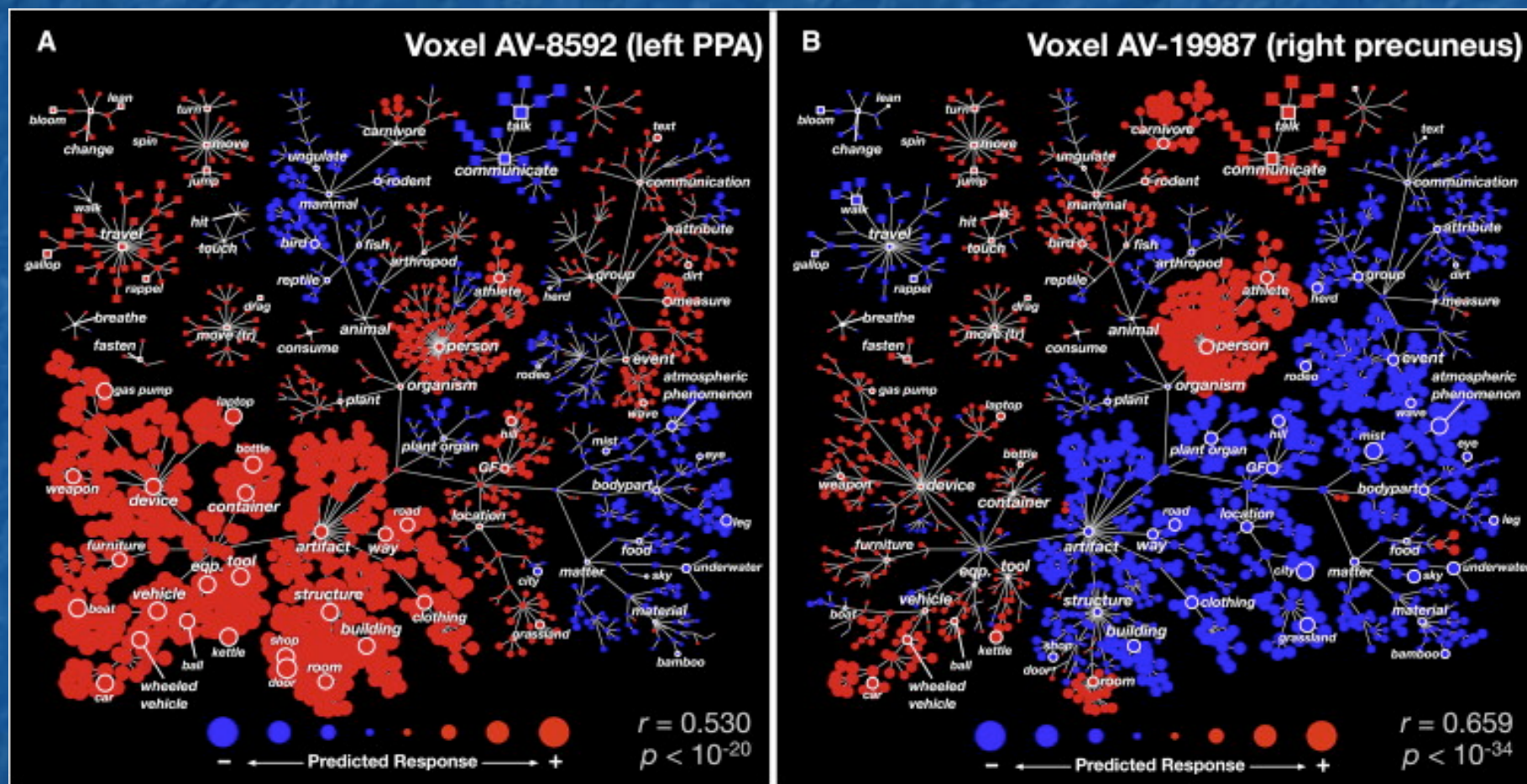
Volumes can be imaged.

Changes in blood flow over time reveal function.

The blood-oxygen level dependent (BOLD) method reveals oxygen supply.

(fMRI)

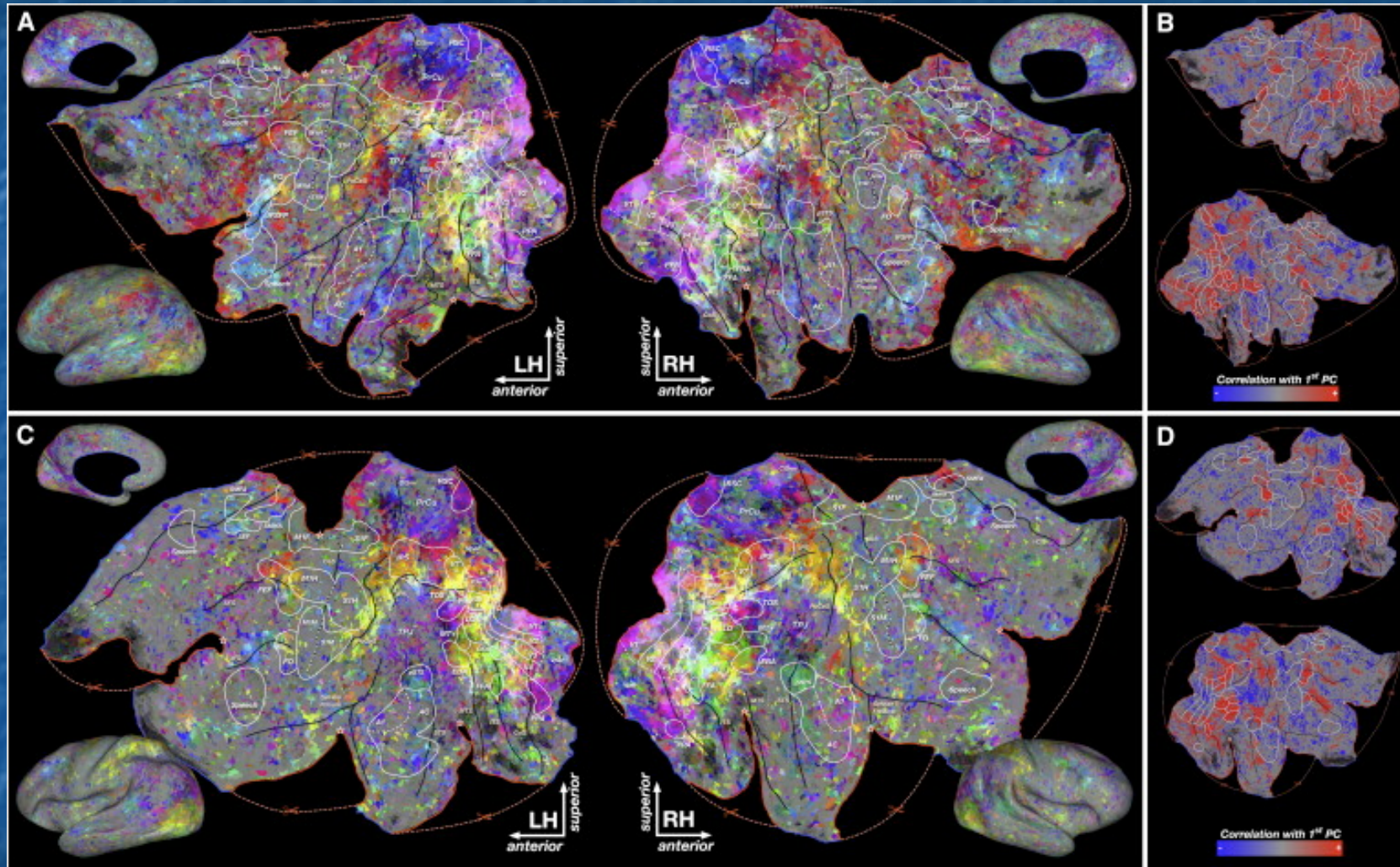
Huth, Nishimoto, Vu & Gallant (2012)



Mapping between 30k voxels and the semantic categories of film trailers

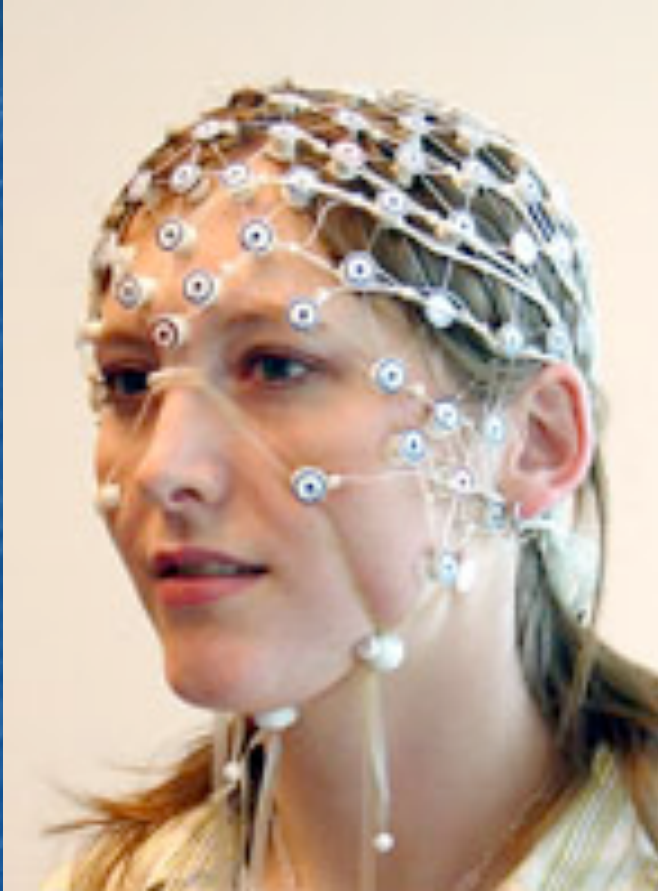
(fMRI)

Huth, Nishimoto, Vu & Gallant (2012)



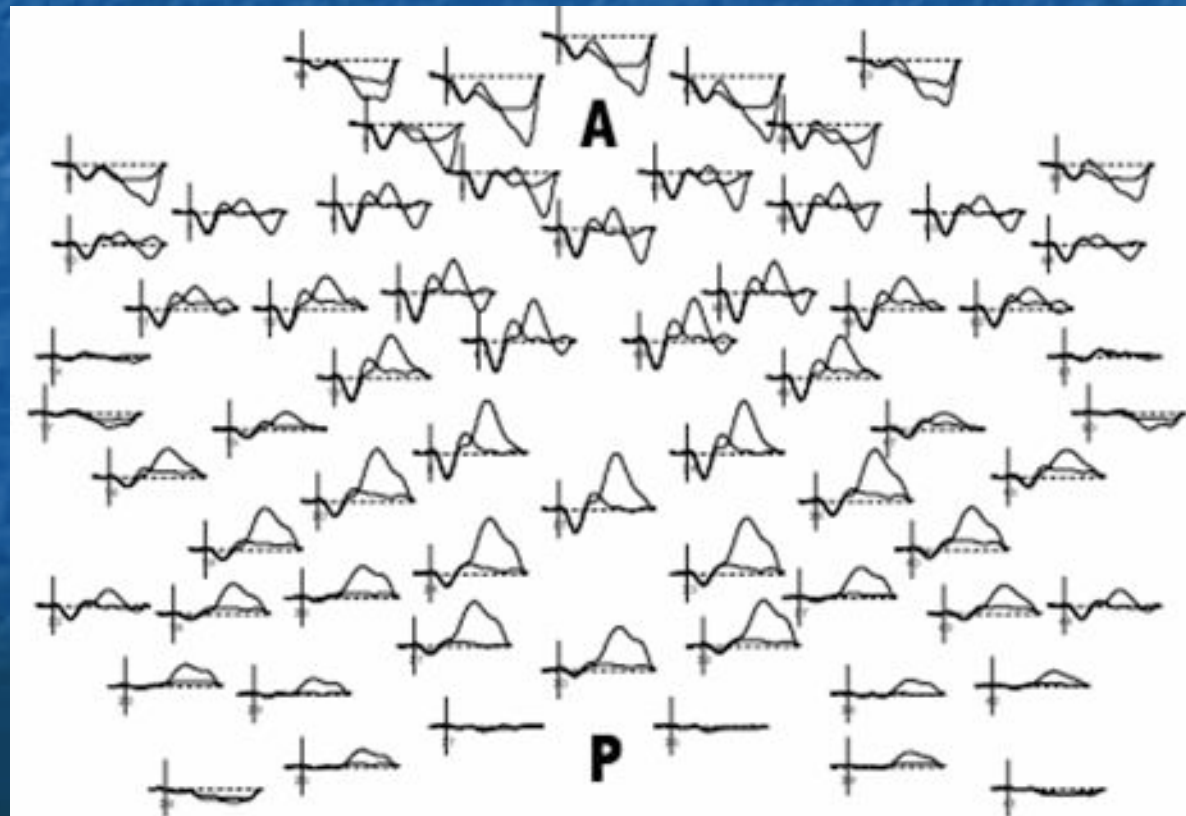
Mapping between 30k voxels and the semantic categories of film trailers.

Electrical activity on the scalp : EEG

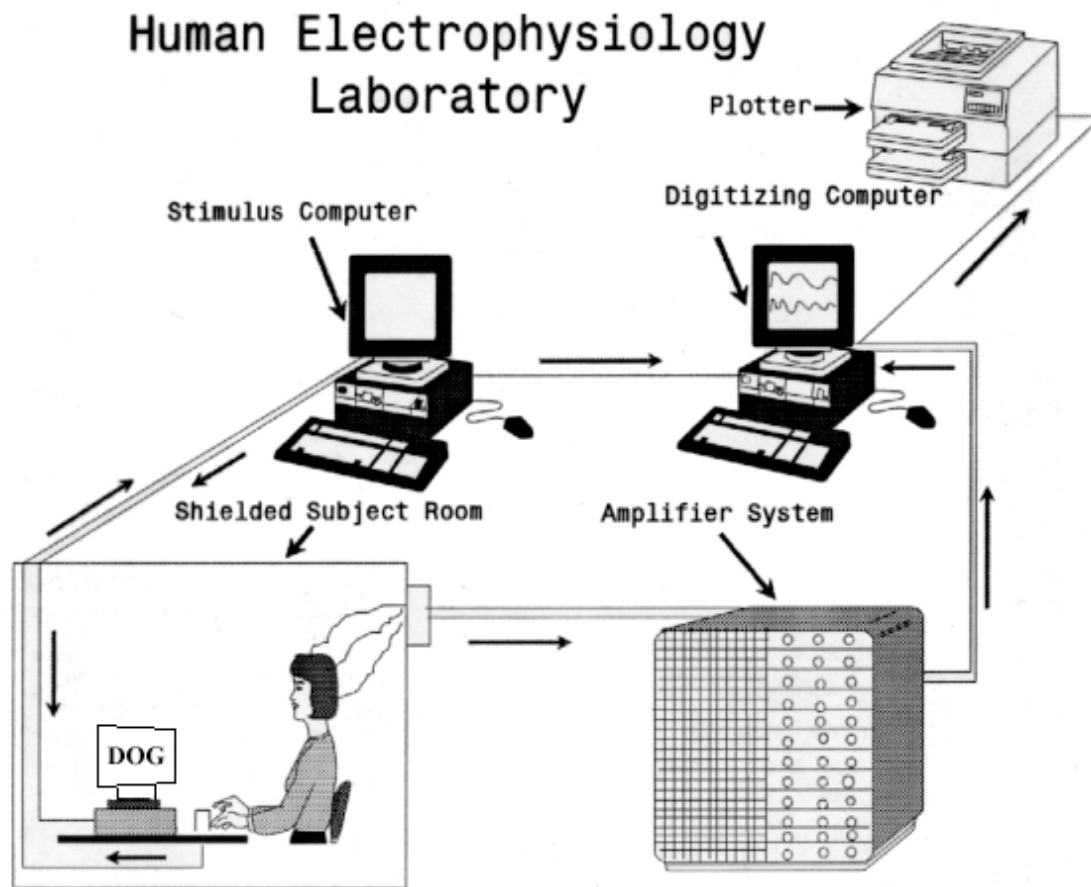


Neurons produce electrochemical activity.

The sum of their activity is detectable on the scalp.

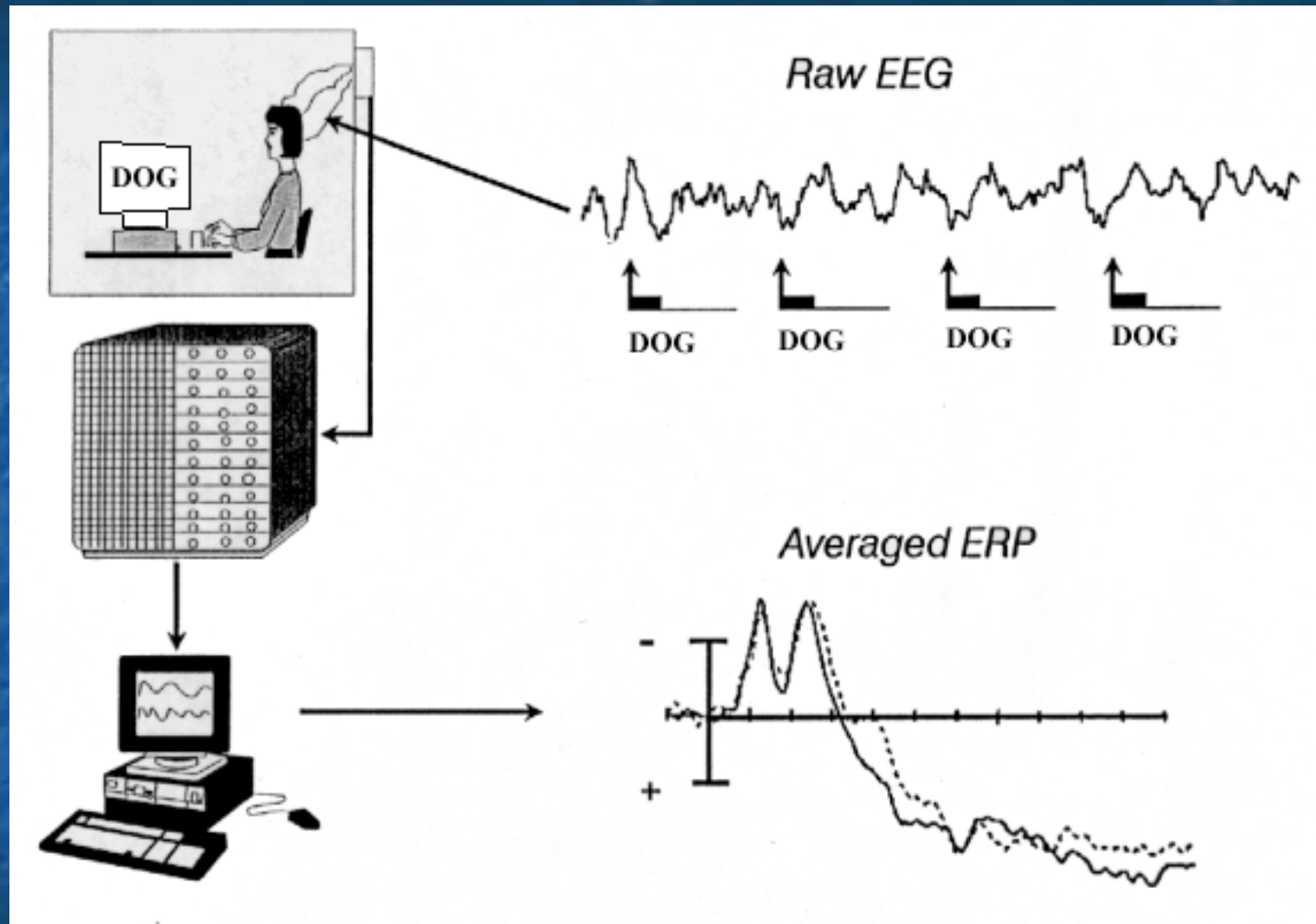


Electrical activity on the scalp : EEG



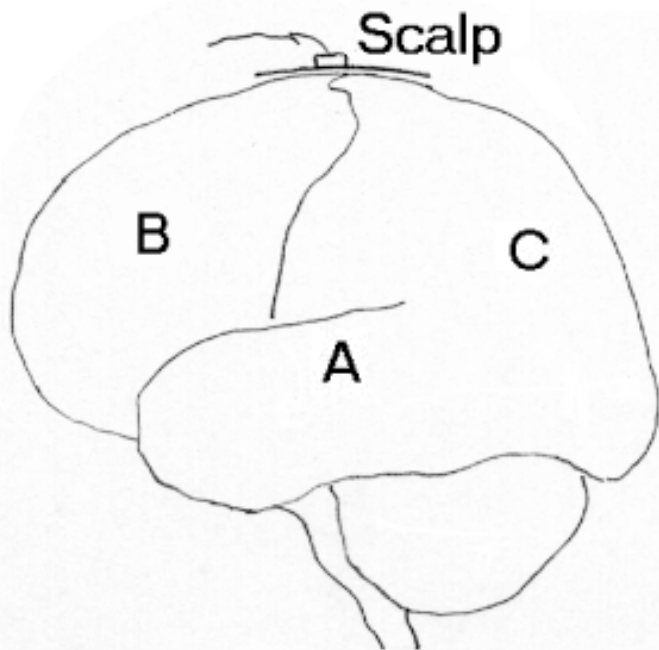
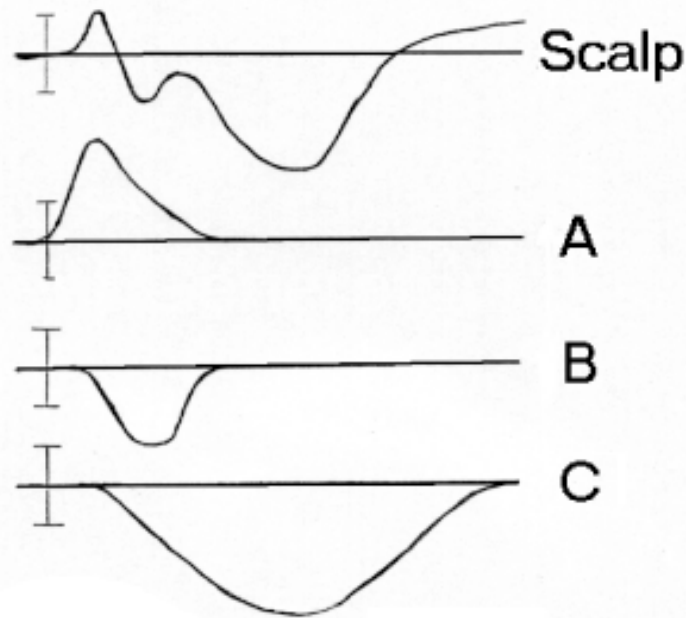
The EEG is the raw activity. There is a relatively small event-related potential (ERP) as the participant responds to stimuli.

Electrical activity on the scalp : EEG



Repeated raw EEG data are averaged to create an ERP.

Electrical activity on the scalp : EEG

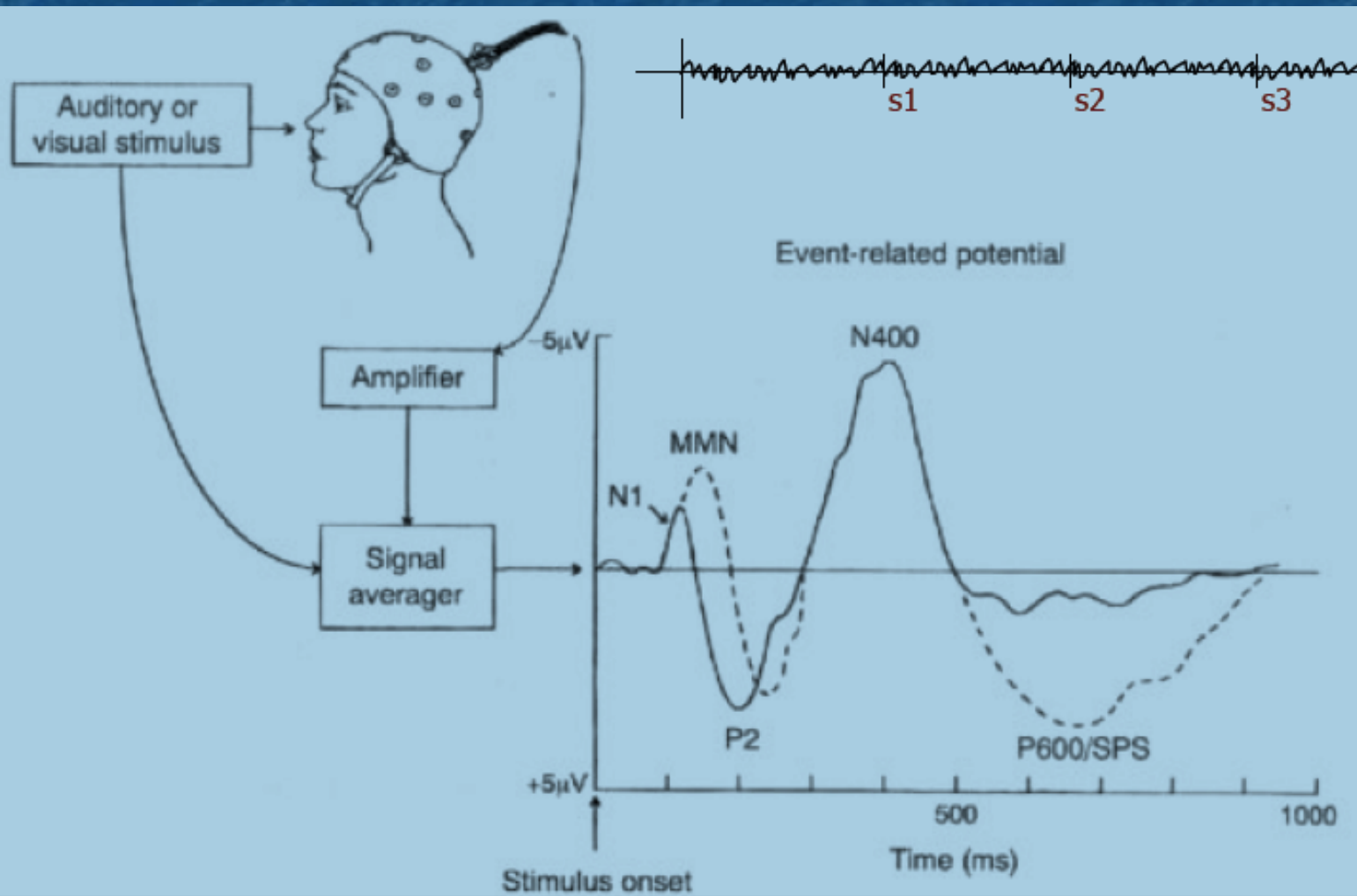


Different generators in different parts of the brain can combine to create the ERP at the scalp.

Nevertheless, location information can be revealed.

Timing is accurate.

Electrical activity on the scalp : EEG

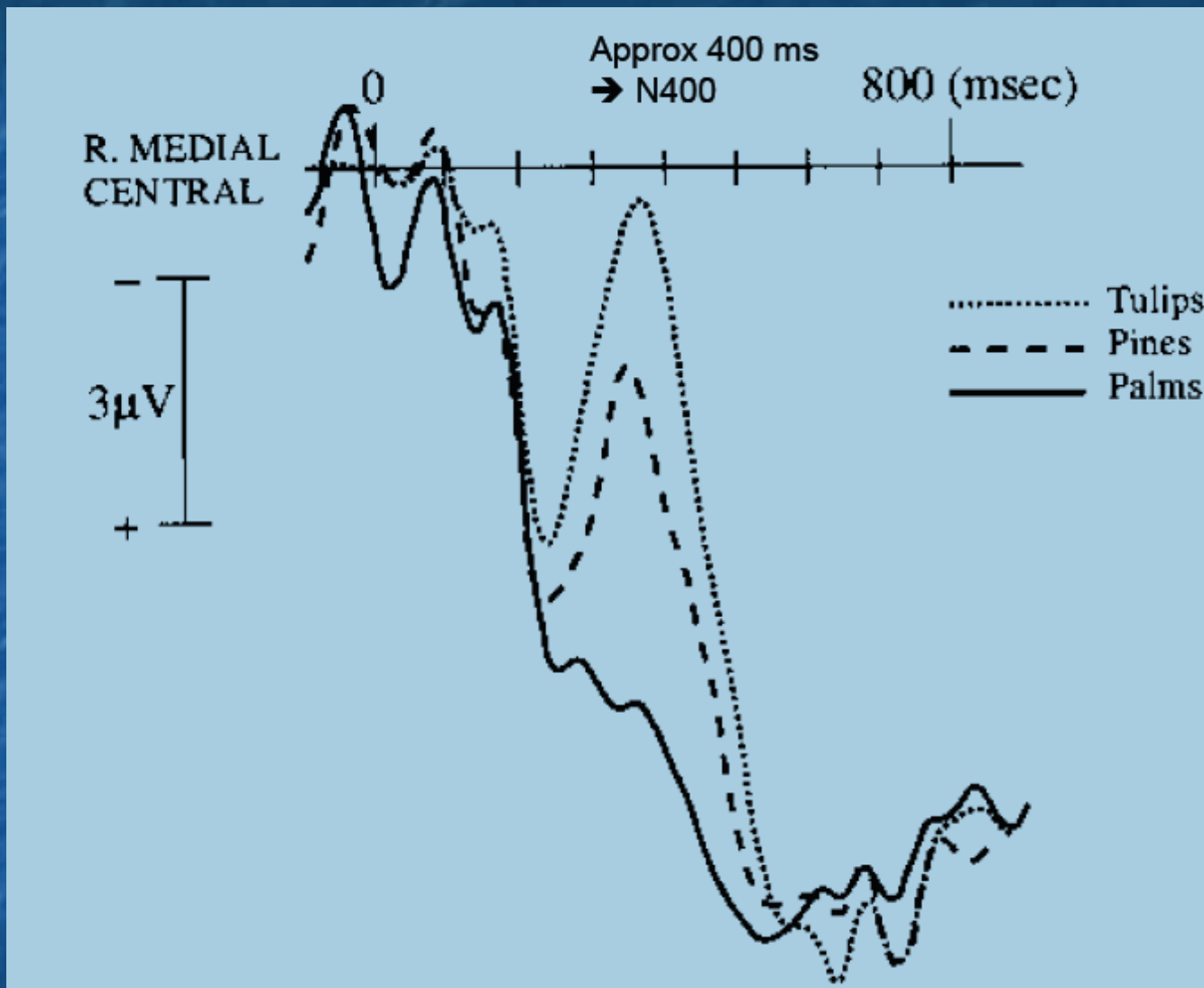


ERPs are referred to as N (negative) or P (positive).

Numbers indicate order of occurrence after the stimulus.

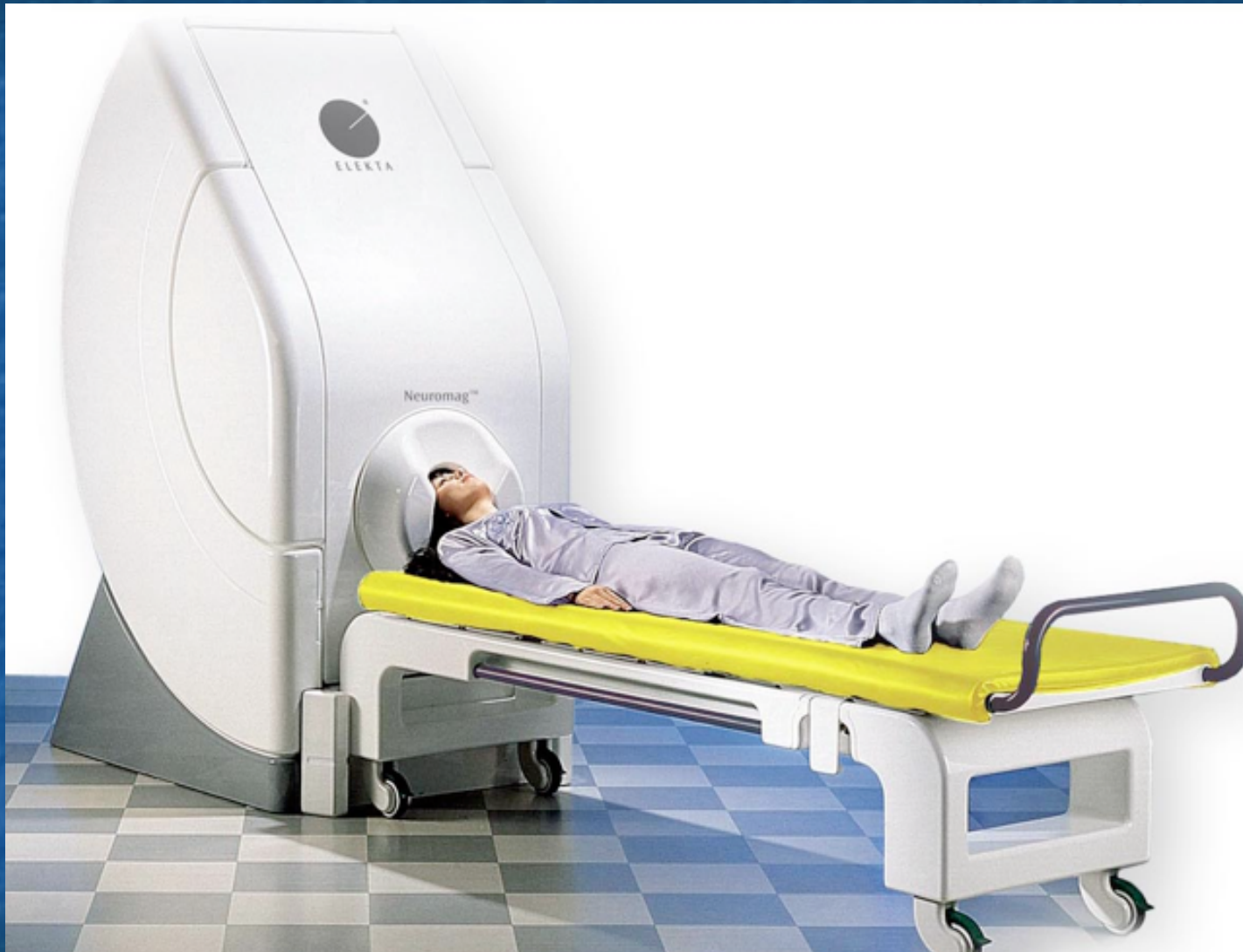ERPs and incongruity

Kutas et al.(1999)



They wanted to make the hotel look like a tropical resort. So along the driveway they planted rows of ..31/41

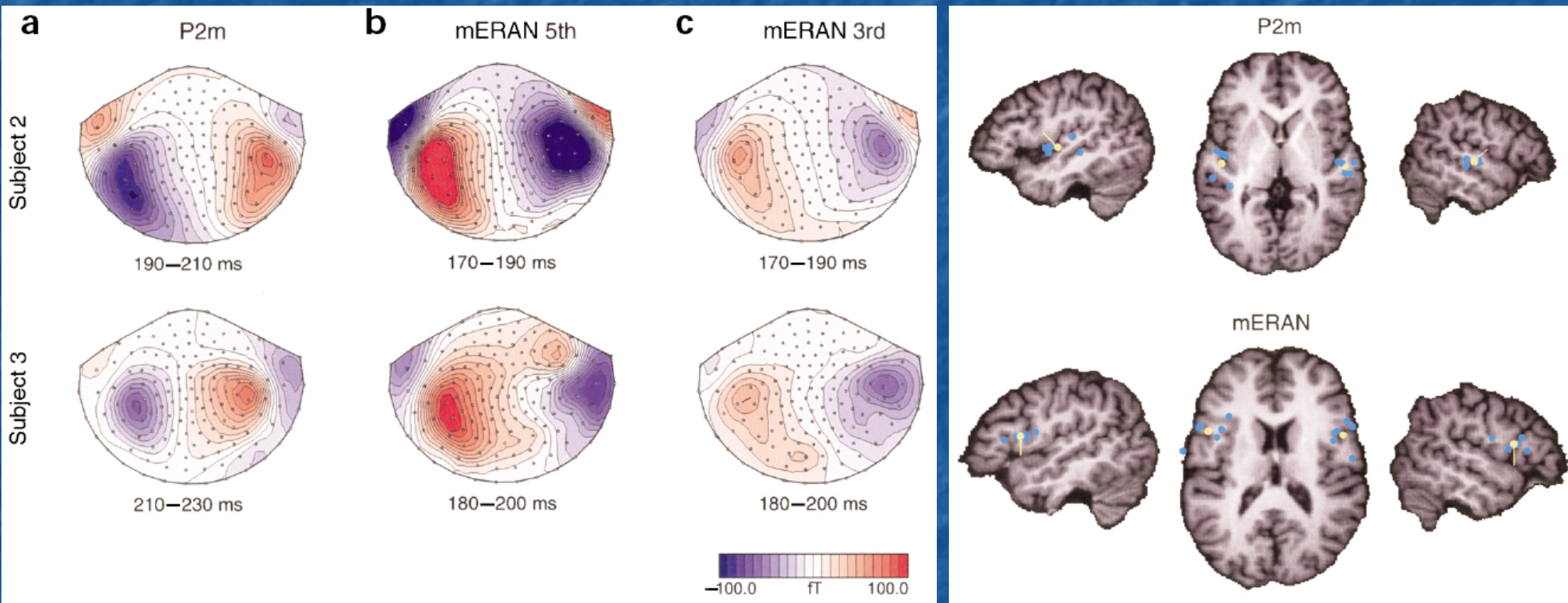
Magneto-encephalography (MEG)



MEG picks up tiny magnetic disturbances outside the skull. It is non-invasive.

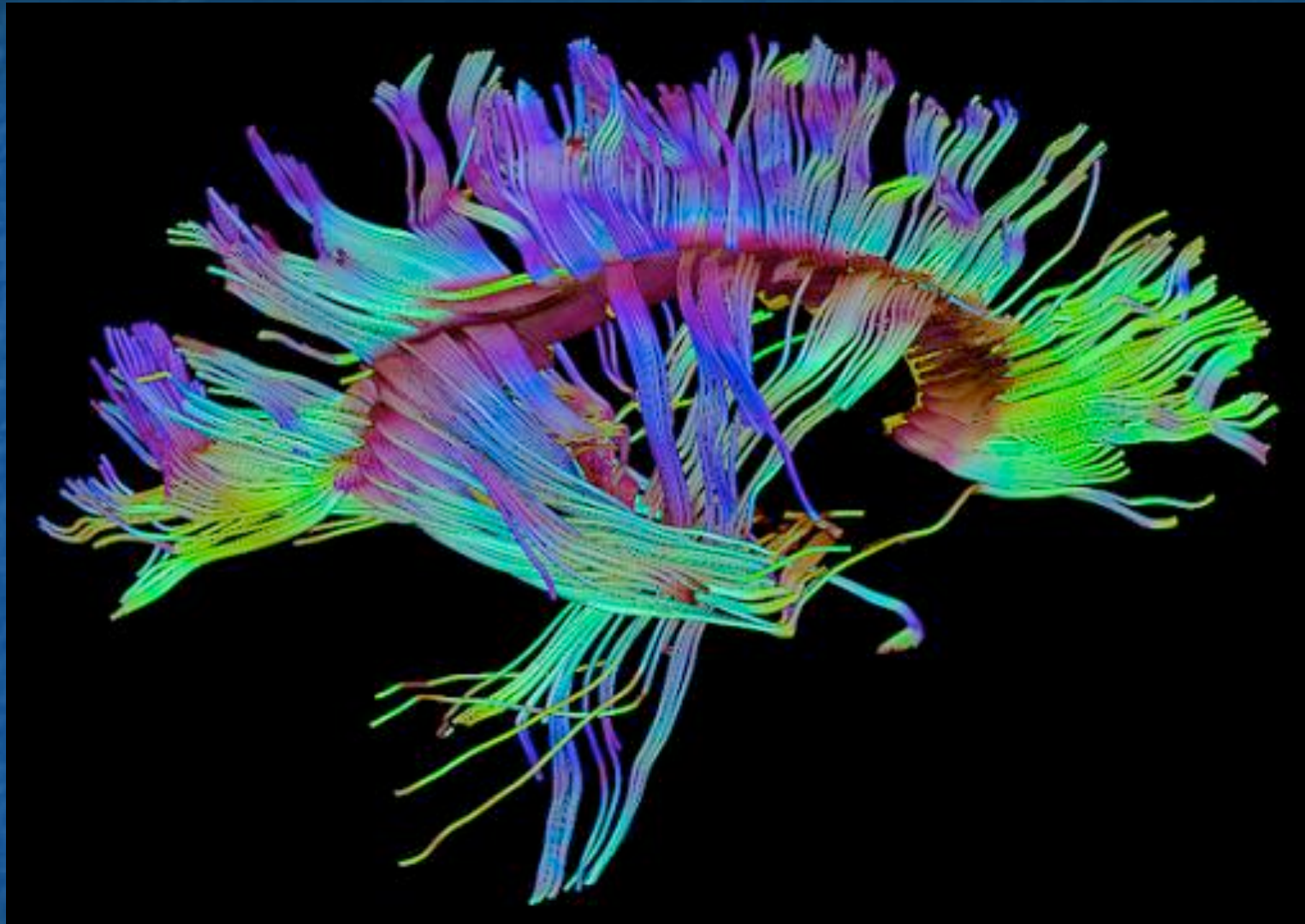
Magneto-encephalography (MEG)

Maess et al. (2001)



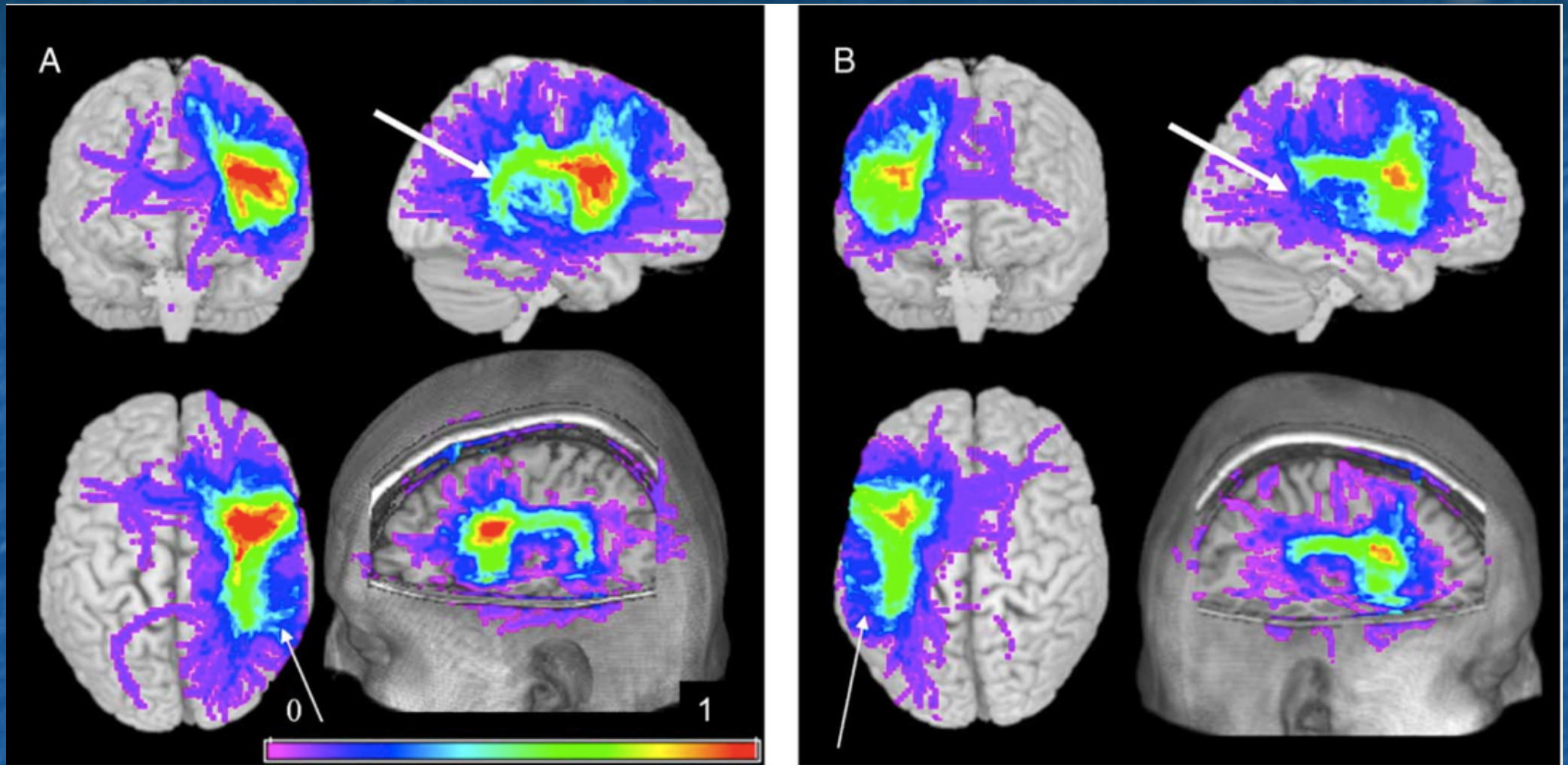
MEG study showing that musical syntax is processed in Broca's area.

Diffusion tensor imaging



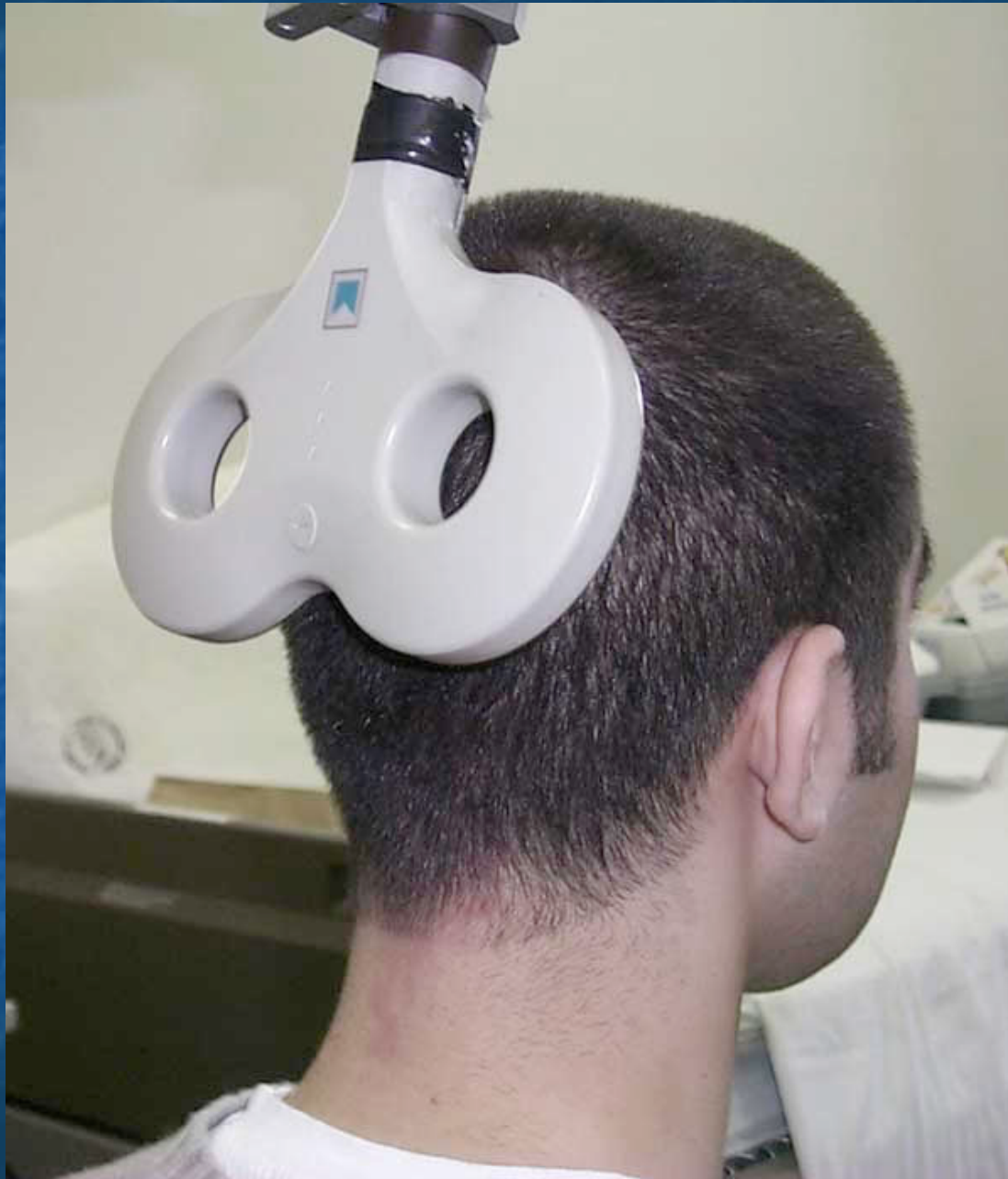Diffusion tensor imaging tracks the paths of fastest diffusion of water molecules in white matter fibres.

Diffusion tensor imaging



Diffusion tensor imaging shows that the white matter connections from Broca's area are more extensive in the LH (Powell, *et al.*, 2006).

Transcranial Magnetic Stimulation



TMS disrupts the electrical activity of the superficial cortex, using a powerful magnetic field.

rTMS does this repetitively.

Function can be localized, in conjunction with a behavioural task.

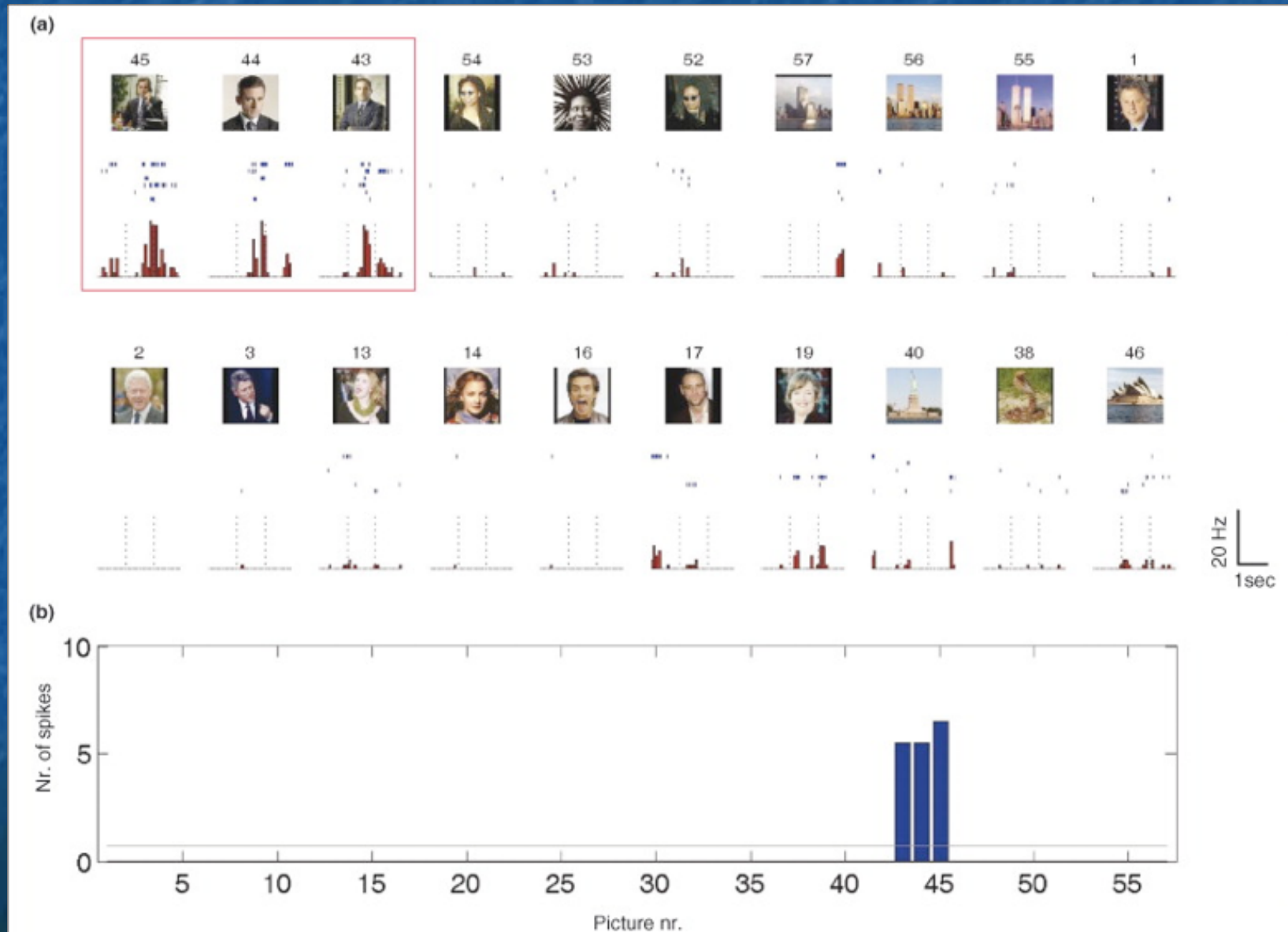
Direct Current Stimulation



The exposed tissue is polarized and tDCS modifies spontaneous neuronal excitability and activity by a tonic de- or hyper-polarization of resting membrane potential.

Single-cell recording

Quian Quiroga, Kreiman, Koch, & Fried (2008)



Challenges

To find ways of applying neuro-imaging to provide unique, detailed information about cognition.

To situate these techniques within sustainable research funding.

To interpret “activity” – or lack of it.

To obtain convergent evidence.

To understand that the assumptions underlying simpler (e.g. response time) techniques may be no less critical.

References

- Mosso, A., & Pellacini, P. (1881). Sulle funzioni della vesica. *Arch Ital Biol*, 12, 3-45.
- Fulton, J. F. (1928). Observations upon the vascularity of the human occipital lobe during visual activity. *Brain*, 51(3), 310-320.
- Obrig, H., Wenzel, R., Kohl, M., Horst, S., Wobst, P., Steinbrink, J., ... & Villringer, A. (2000). Near-infrared spectroscopy: does it function in functional activation studies of the adult brain? *International Journal of Psychophysiology*, 35(2), 125-142.
- Bortfeld, H., Wruck, E., & Boas, D. A. (2007). Assessing infants' cortical response to speech using near-infrared spectroscopy. *Neuroimage*, 34(1), 407-415.
- Knecht, S., Deppe, M., Ebner, A., Henningsen, H., Huber, T., Jokeit, H., & Ringelstein, E. B. (1998). Non-invasive determination of hemispheric language dominance using functional transcranial Doppler sonography: a comparison with the Wada test. *Stroke*, 29(1), 82-86.
- Posner, M. I., & Raichle, M. E. (1994). *Images of mind*. Scientific American Library/Scientific American Books.
- Vargha-Khadem, F., Watkins, K., Alcock, K., Fletcher, P., & Passingham, R. (1995). Praxic and nonverbal cognitive deficits in a large family with a genetically transmitted speech and language disorder. *Proceedings of the National Academy of Sciences*, 92(3), 930-933.
- Huth, A. G., Nishimoto, S., Vu, A. T., & Gallant, J. L. (2012). A continuous semantic space describes the representation of thousands of object and action categories across the human brain. *Neuron*, 76(6), 1210-1224.
- Federmeier, K. D., & Kutas, M. (1999). A rose by any other name: Long-term memory structure and sentence processing. *Journal of Memory and Language*, 41(4), 469-495.

References

- Maess, B., Koelsch, S., Gunter, T. C., & Friederici, A. D. (2001). Musical syntax is processed in Broca's area: an MEG study. *Nature neuroscience*, 4(5), 540-545.
- Powell, H. W., Parker, G. J., Alexander, D. C., Symms, M. R., Boulby, P. A., Wheeler-Kingshott, C. A., ... & Duncan, J. S. (2006). Hemispheric asymmetries in language-related pathways: a combined functional MRI and tractography study. *Neuroimage*, 32(1), 388-399.
- Quiroga, R. Q., Kreiman, G., Koch, C., & Fried, I. (2008). Sparse but not 'grandmother-cell' coding in the medial temporal lobe. *Trends in Cognitive Sciences*, 12(3), 87-91.